دانشگاه علوم پزشکی و خدمات بهداشتی، درمانی ایران

Artificial Intelligence in Ophthalmology

دکتر نسیبه رادی راز

Dr. Nasibeh Rady Raz

PhD in Artificial Intelligence and Robotics

Assistant Professor in Artificial Intelligence in Medicine, Faculty of Advanced Technologies in Medicine, Iran University of Medical Sciences, Tehran, Iran

radyraz.n@iums.ac.ir

دانشگاه علوم پزشکی و خدمات بهداشتی، درمانی ایران

بسم الله الرحمن الرحیم

دانشگاه علوم پزشکی و خدمات بهداشتی، درمانی ایران

عنوان دوره آنلاین:

هوش مصنوعی در پزشکی با رویکرد بالینی

Online Course: Artificial Intelligence in Medicine with Clinical Approach

Course Topics	عناوین بیست و چهار جلسه	تاریخ جلسات
Artificial Intelligence (AI) in medicine	معرفی هوش مصنوعی در پزشکی	۲۸ بهمن ۱۴۰۲
AI and Fuzzy systems and its applications in medicine	هوش مصنوعی و سیستم های فازی در پزشکی	۵ اسفند ۱۴۰۲
Machine Learning and its applications in medicine	یادگیری ماشین و کاربردهای آن در پزشکی	۱۲اسفند۱۴۰۲
Evolutionary systems and its applications in medicine	الگوریتم های بهینه سازی تکاملی و کاربردهای آن در پزشکی	۱۹اسفند ۱۴۰۲
Neural networks and deep neural networks in medicine	شبکه های عصبی و شبکه های عصبی عمیق در پزشکی	۲۵فروردین ۱۴۰۳
Application of AI in Early Detection of Disease	کاربرد هوش مصنوعی در تشخیص زودهنگام بیماری ها	۱ اردیبهشت ۱۴۰۳
Swarm Intelligence and multi-agent/swarm in medicine	هوش ازدحامی، سیستم های چند عامله/ازدحامی در پزشکی	۸اردیبهشت ۱۴۰۳
Application of AI in Cancer	کاربردهای هوش مصنوعی در سرطان	۲۲اردیبهشت ۱۴۰۳
Application of AI in surgery	کاربردهای هوش مصنوعی در جراحی	۲۹ اردیبهشت ۱۴۰۳
Applications of AI in Neurology	کاربردهای هوش مصنوعی در مغز و اعصاب	۵ خرداد ۱۴۰۳
Application of AI in Internal Medicine	کاربردهای هوش مصنوعی در پزشکی داخلی	۱۲ خرداد ۱۴۰۳
Applications of AI in cardiovascular	کاربردهای هوش مصنوعی در قلب و عروق	۱۹ خرداد ۱۴۰۳
Applications of AI in Breast Disease	کاربردهای هوش مصنوعی در بیماری های پستان	۲۶ خرداد ۱۴۰۳
Application of AI in Ophthalmology	کاربردهای هوش مصنوعی در چشم پزشکی	۲ تیر ۱۴۰۳
Application of AI in Nephrology	کاربردهای هوش مصنوعی در نفرولوژی	۹ تیر ۱۴۰۳
Application of AI in Otorhinolaryngology	کاربردهای هوش مصنوعی در گوش و حلق و بینی	۱۶ تیر ۱۴۰۳
Application of AI in Gynecology and obstetrics	کاربردهای هوش مصنوعی در زنان و مامایی	۲۳ تیر ۱۴۰۳
Application of AI in pediatric medicine	کاربردهای هوش مصنوعی در پزشکی اطفال	۳۰ تیر ۱۴۰۳
Application of AI in anesthesia	کاربردهای هوش مصنوعی در بیهوشی	۶ مرداد ۱۴۰۳
Application of AI in emergency medicine	کاربردهای هوش مصنوعی در پزشکی اورژانس	۱۳ مرداد ۱۴۰۳
Applications of artificial intelligence in orthopedics	کاربردهای هوش مصنوعی در ارتوپدی	۲۰ مرداد ۱۴۰۳
Application of AI in pain management	کاربردهای هوش مصنوعی در مدیریت درد	۲۷ مرداد ۱۴۰۳
Application of AI in pharmacology	کاربردهای هوش مصنوعی در داروسازی	۳ شهریور ۱۴۰۳
Application of AI in dentistry	کاربردهای هوش مصنوعی در دندان پزشکی	۱۰ شهریور ۱۴۰۳

AI Tools

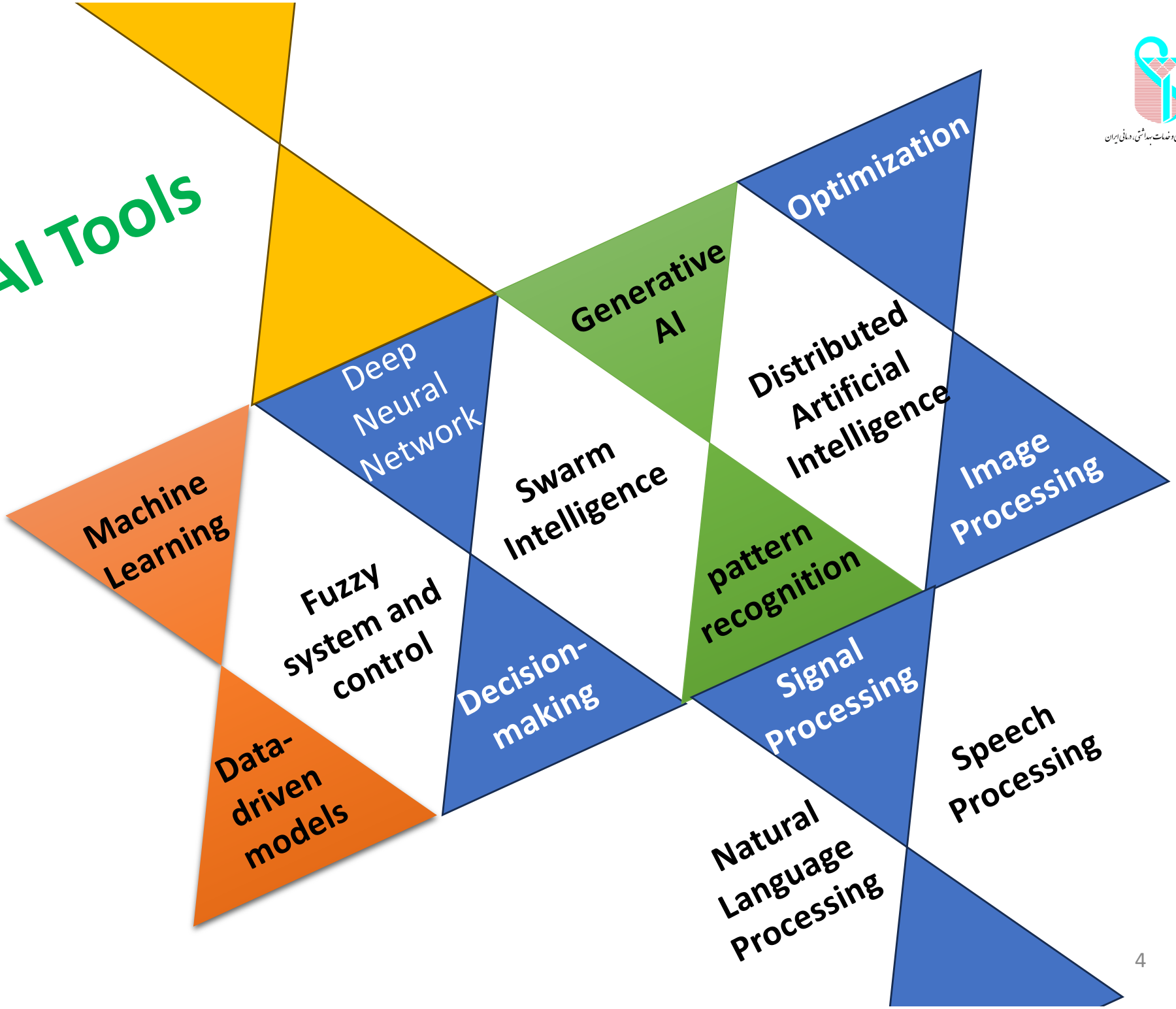
Machine Learning
Deep Neural Network
Generative AI
Optimization
Fuzzy system and control
Swarm Intelligence
Distributed Artificial Intelligence
Image Processing
Data-driven models
Decision-making
pattern recognition
Signal Processing
Speech Processing
Natural Language Processing

Ophthalmology

Ophthalmology is a clinical and surgical specialty within medicine that deals with the diagnosis and treatment of eye disorders.

Eye

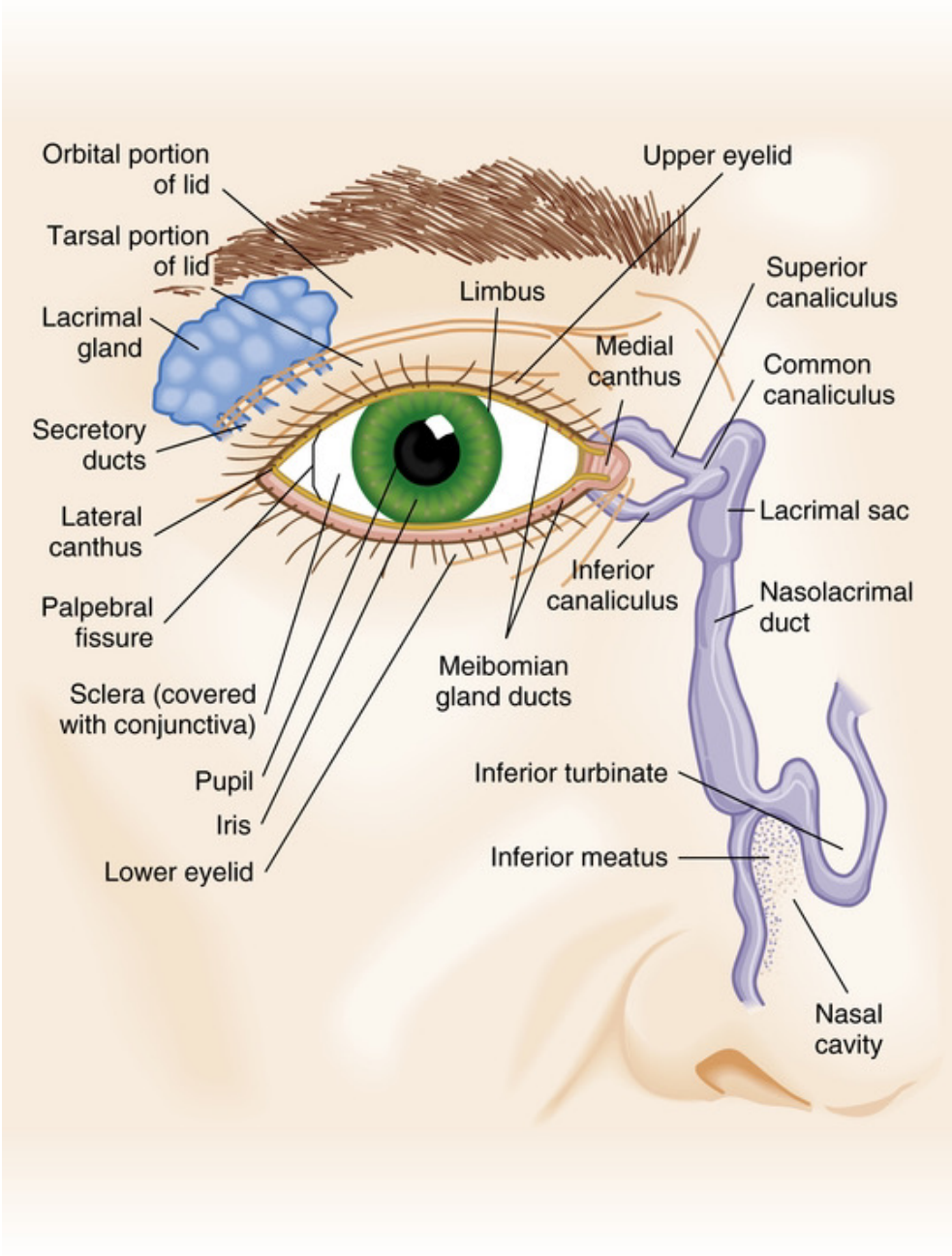
Orbital portion of lid
Tarsal portion of lid
Lacrimal gland
Secretory ducts
Lateral canthus
Palpebral fissure
Sclera (covered with conjunctiva)
Pupil
Iris
Lower eyelid
Limbus
Upper eyelid
Medial canthus
Superior canaliculus
Common canaliculus
Lacrimal sac
Inferior canaliculus
Nasolacrimal duct
Meibomian gland ducts
Inferior turbinate
Inferior meatus
Nasal cavity

Eye Anatomy

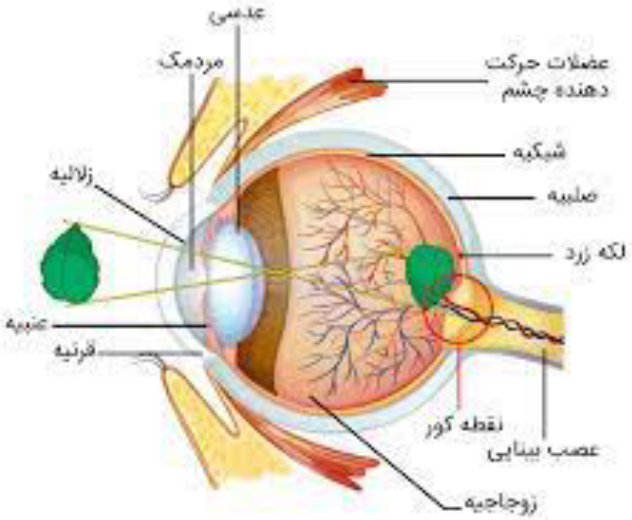

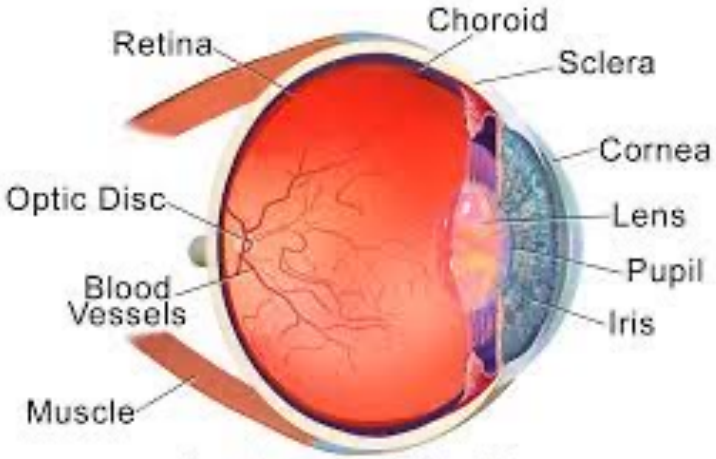

Anatomy of the Eye

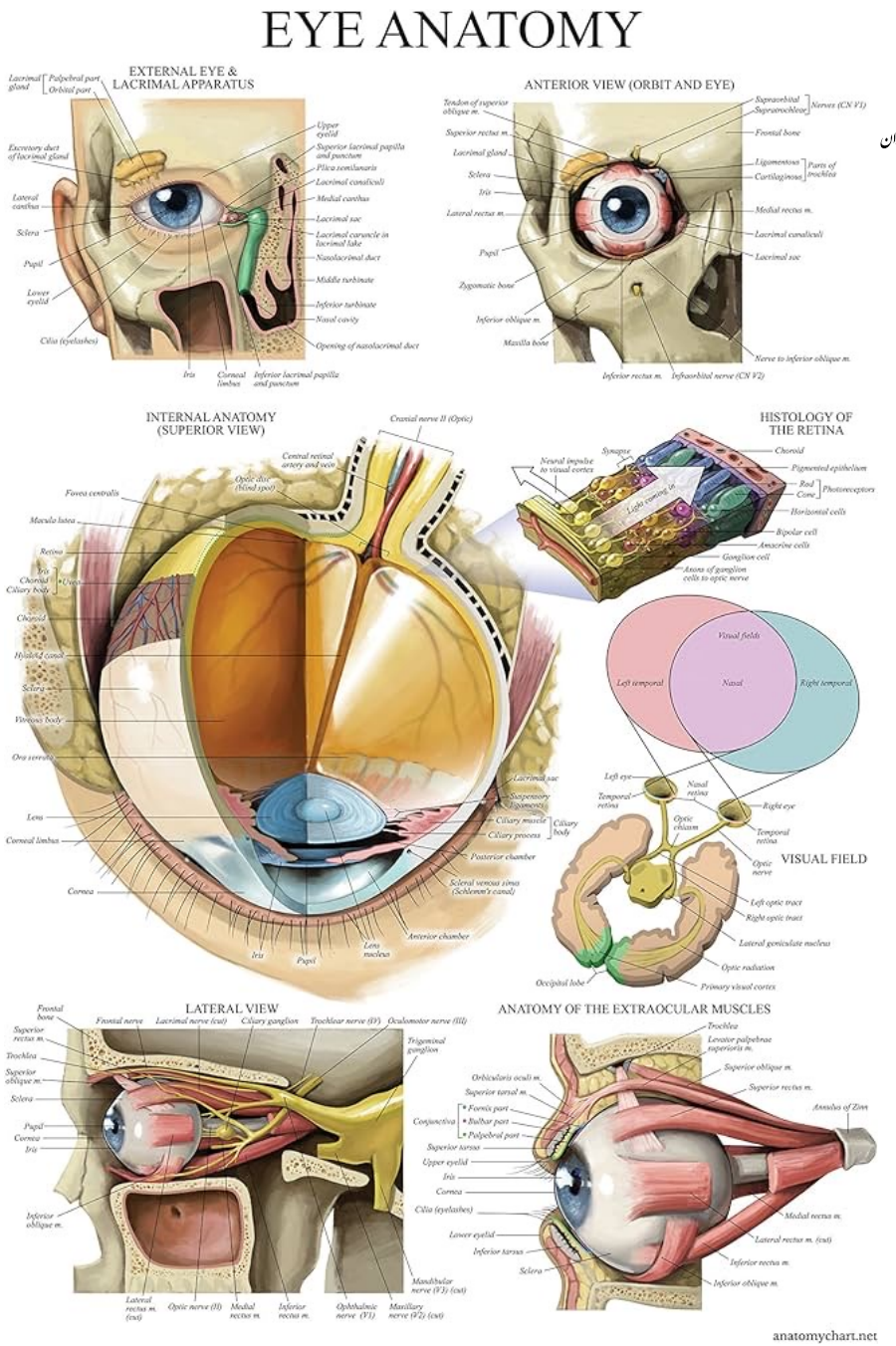

A great Bless

AI in Ophthalmology

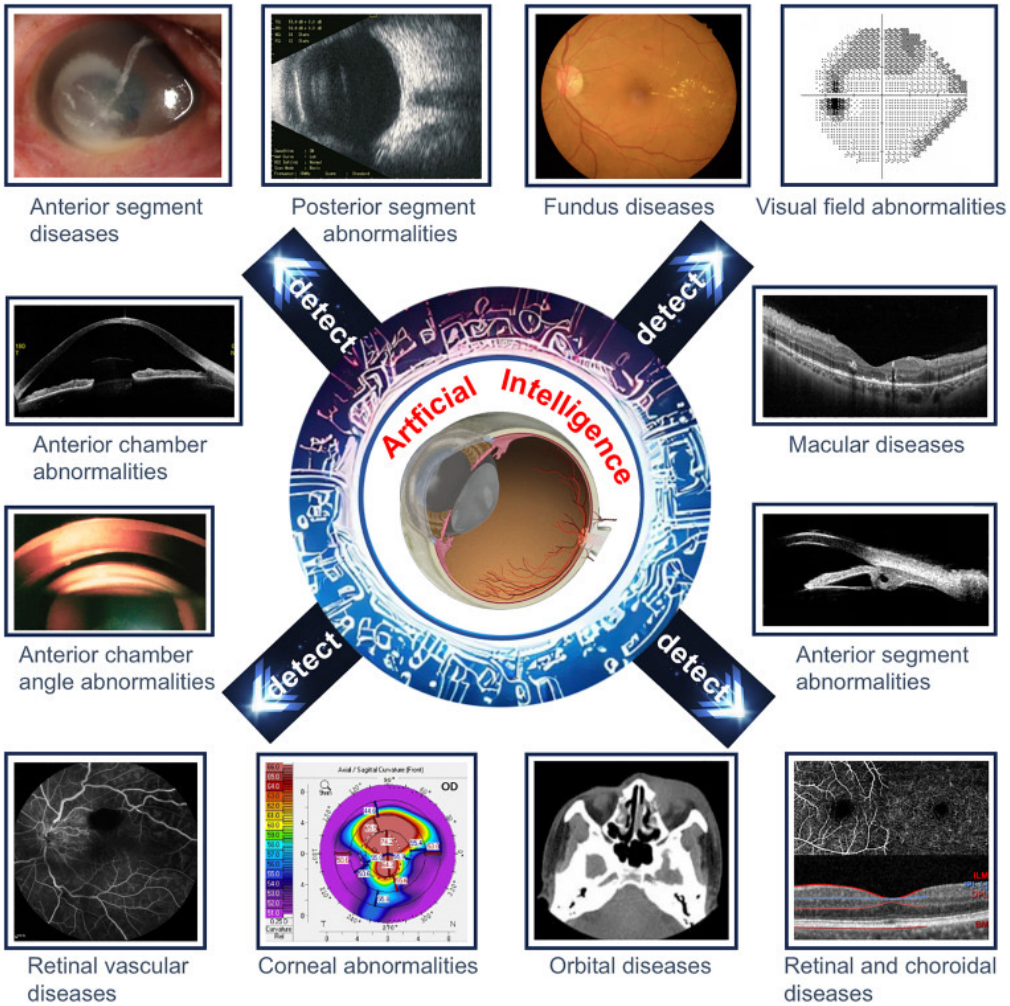

Cell Reports Medicine Volume 4, Issue 7, 18 July 2023, 101095

Application of AI algorithms in posterior-segment eye diseases

- diabetic retinopathy (DR): microvascular damage and retinal dysfunction and vision loss.

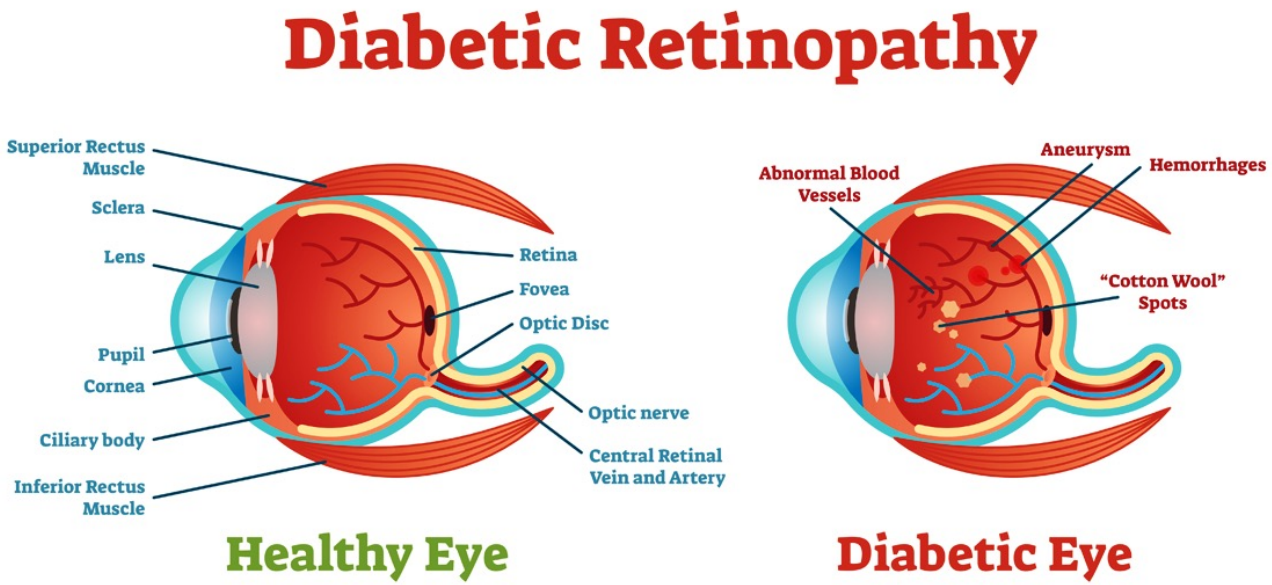

blood vessels can swell and leak. Or they can close, stopping blood from passing through. Sometimes abnormal, new blood vessels grow on the retina

Glaucoma

- Glaucoma, characterized by cupping of the optic disc and visual field impairment, is the most frequent cause of irreversible blindness.

age-related macular degeneration (AMD),

- a disease that affects the macular area of the retina often causes progressive loss of central vision. Age is the strongest risk factor .

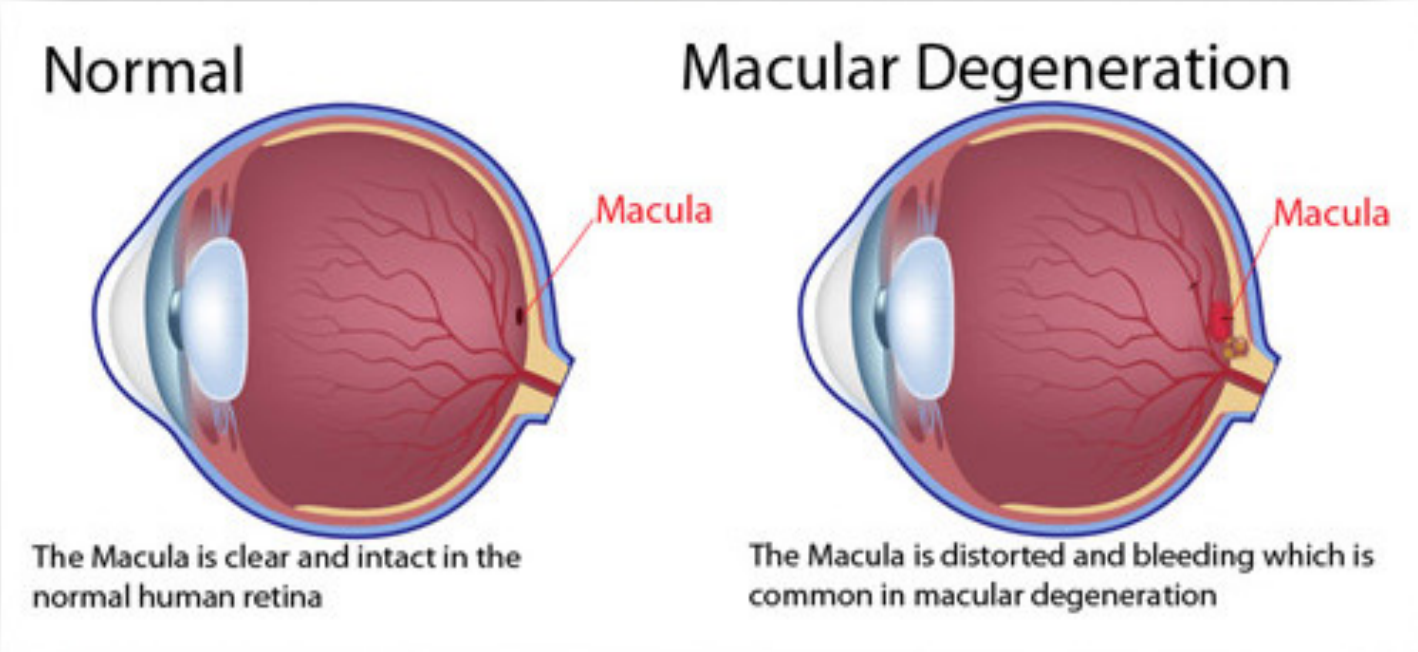

Cataract

- a cloudy area in the lens of your eye

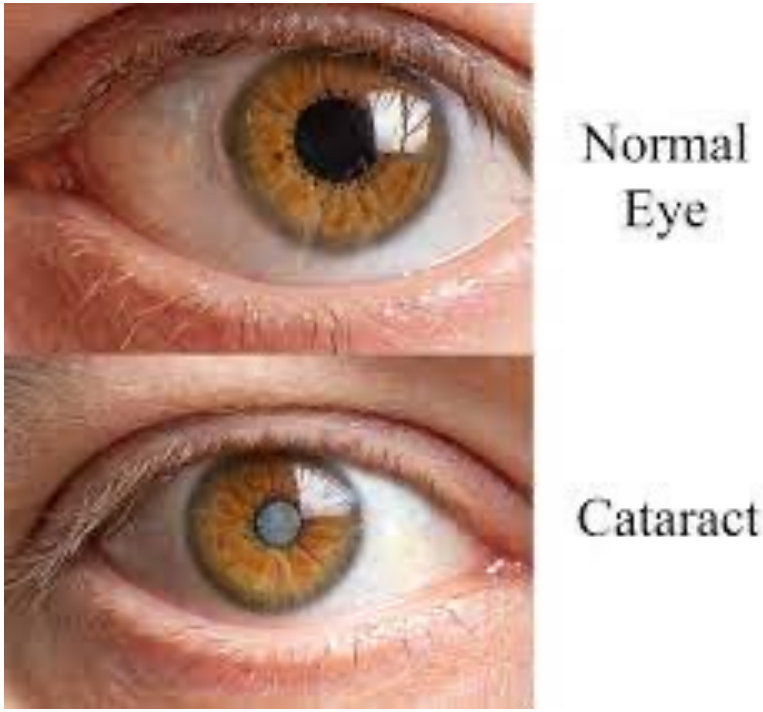

Keratitis

- Keratitis is a major global cause of corneal blindness. corneal ulcer, is an inflammation or irritation of the cornea.

Keratoconus

- progressive corneal ectasia with central or paracentral stroma thinning and corneal protrusion, resulting in irreversible visual impairment due to irregular corneal astigmatism or the loss of corneal transparency.

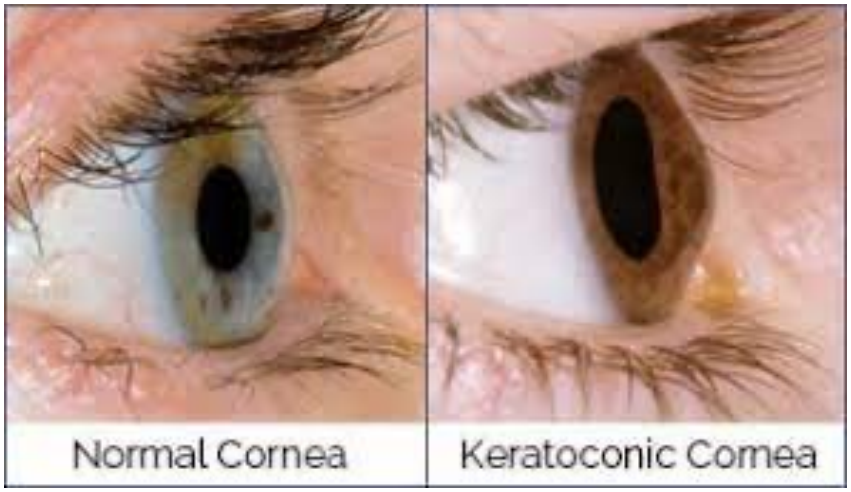

Ocular Oncology

Uveal melanoma

- Uveal melanoma (UM) is the most common primary intraocular malignancy in adults.

Ocular surface tumor

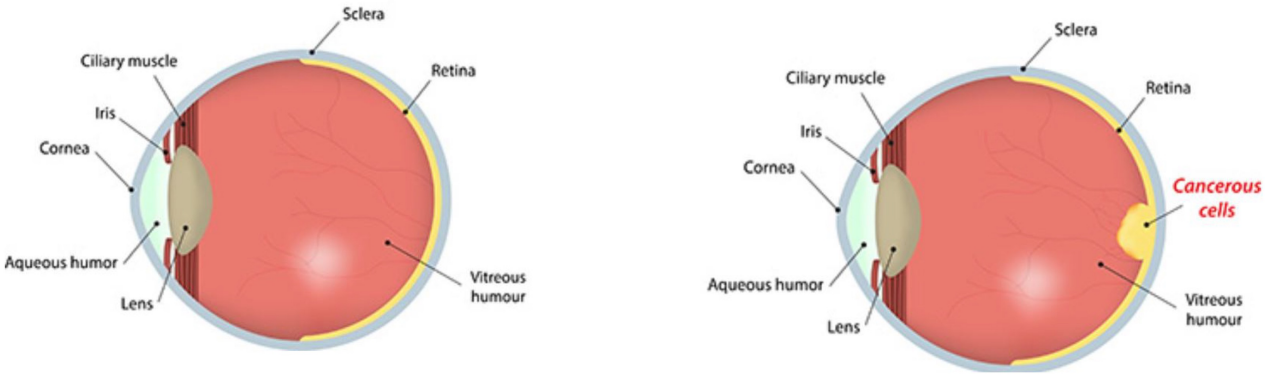

(**a**) Healthy eye (**b**) Retinoblastoma eye

Retinoblastoma

Retinoblastoma is a tumor that could benefit from more ML predictions, since biopsies of these tumors are currently contraindicated due to the risk of tumor spread outside the eye.

Retinal imaging modalities

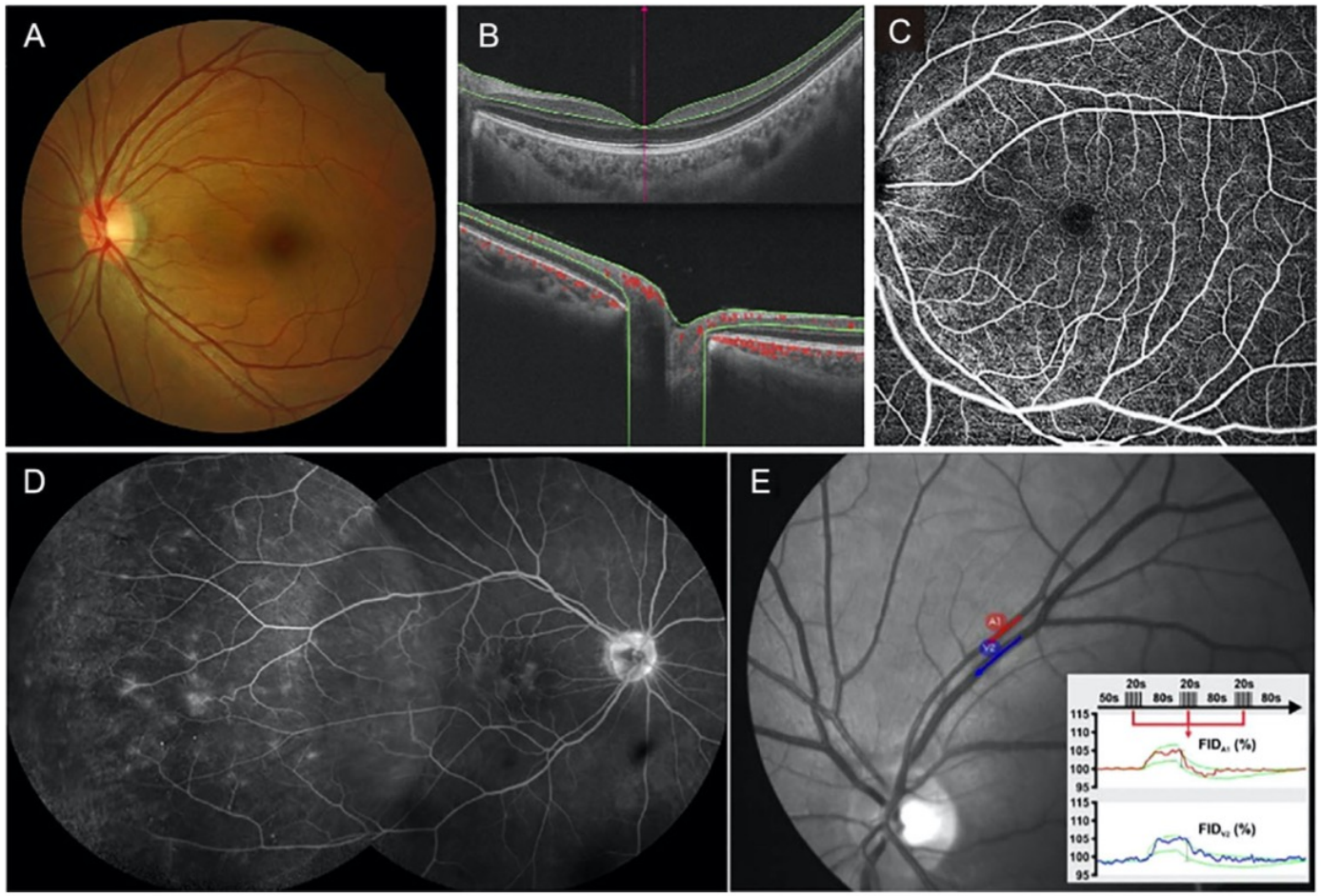

A)Colorfundusphotography;(B)Opticalcoherencetomography(OCT);(C)opticalcoherence tomography angiography (OCT-A); (D) Fluorescein angiography (FA); (E) dynamic retinal vessel analysis (DVA).

Deep learning algorithm predicts diabetic retinopathy progression in individual patients

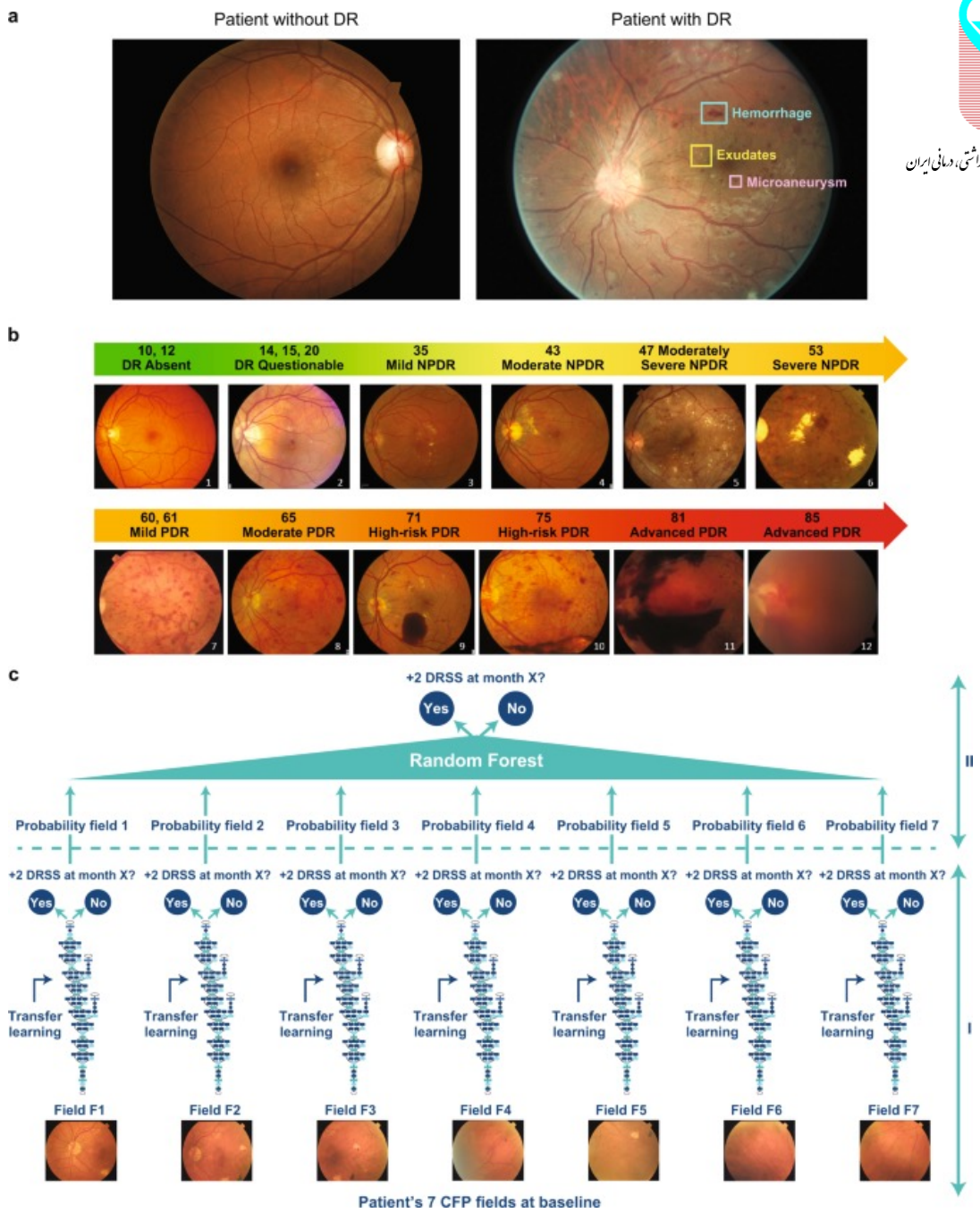

npj Digital Medicine **volume 2**, Article number: 92 (2019)

Deep Learning Predicts OCT Measures of Diabetic Macular Thickening From Color Fundus Photographs

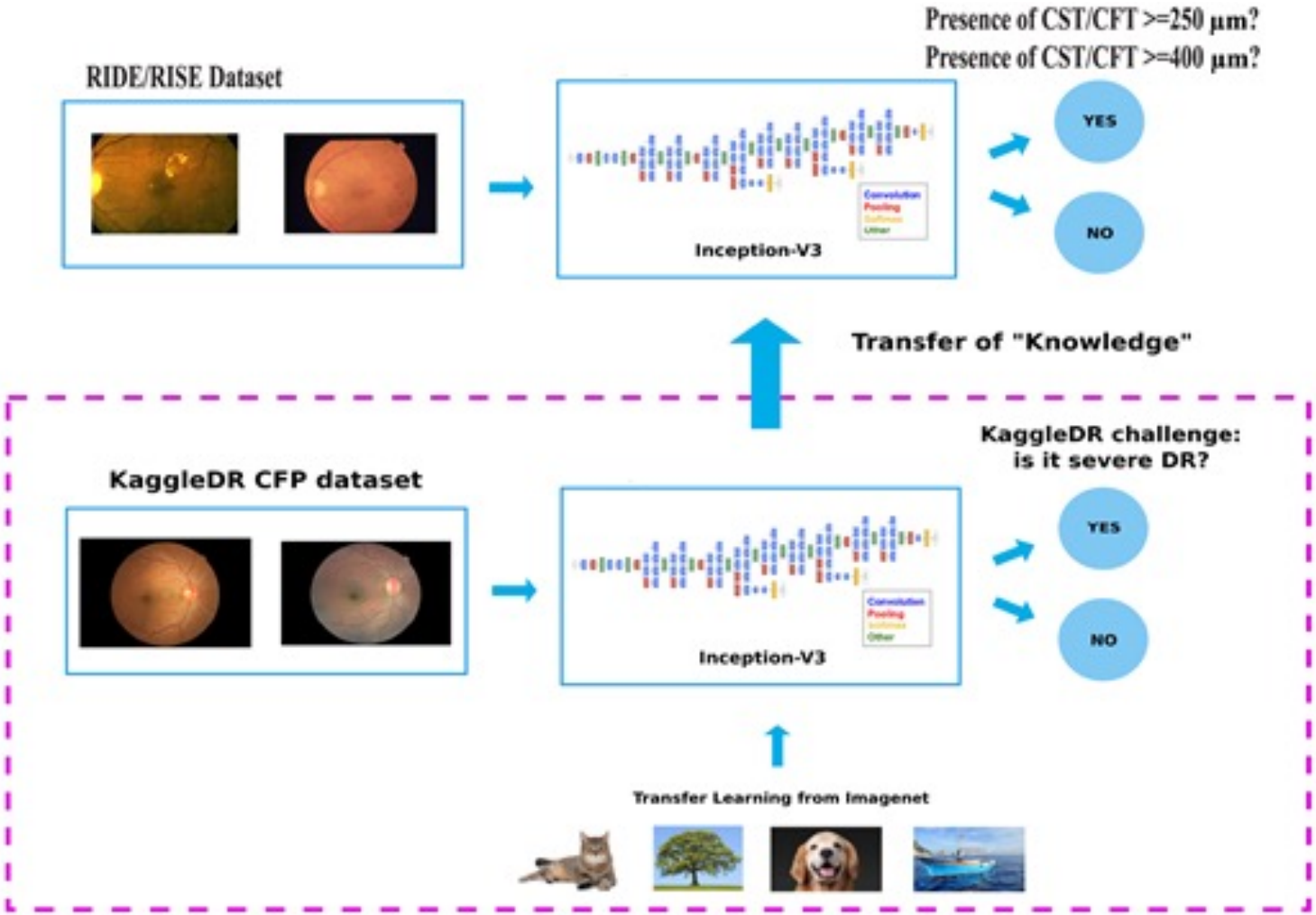

Investigative Ophthalmology & Visual Science March 2019, Vol.60, 852-857.

Application of AI algorithms in predictin systemic diseases based on retinal images

- AI has the potential to detect hidden information that clinicians are normally unable to perceive from digital health data.

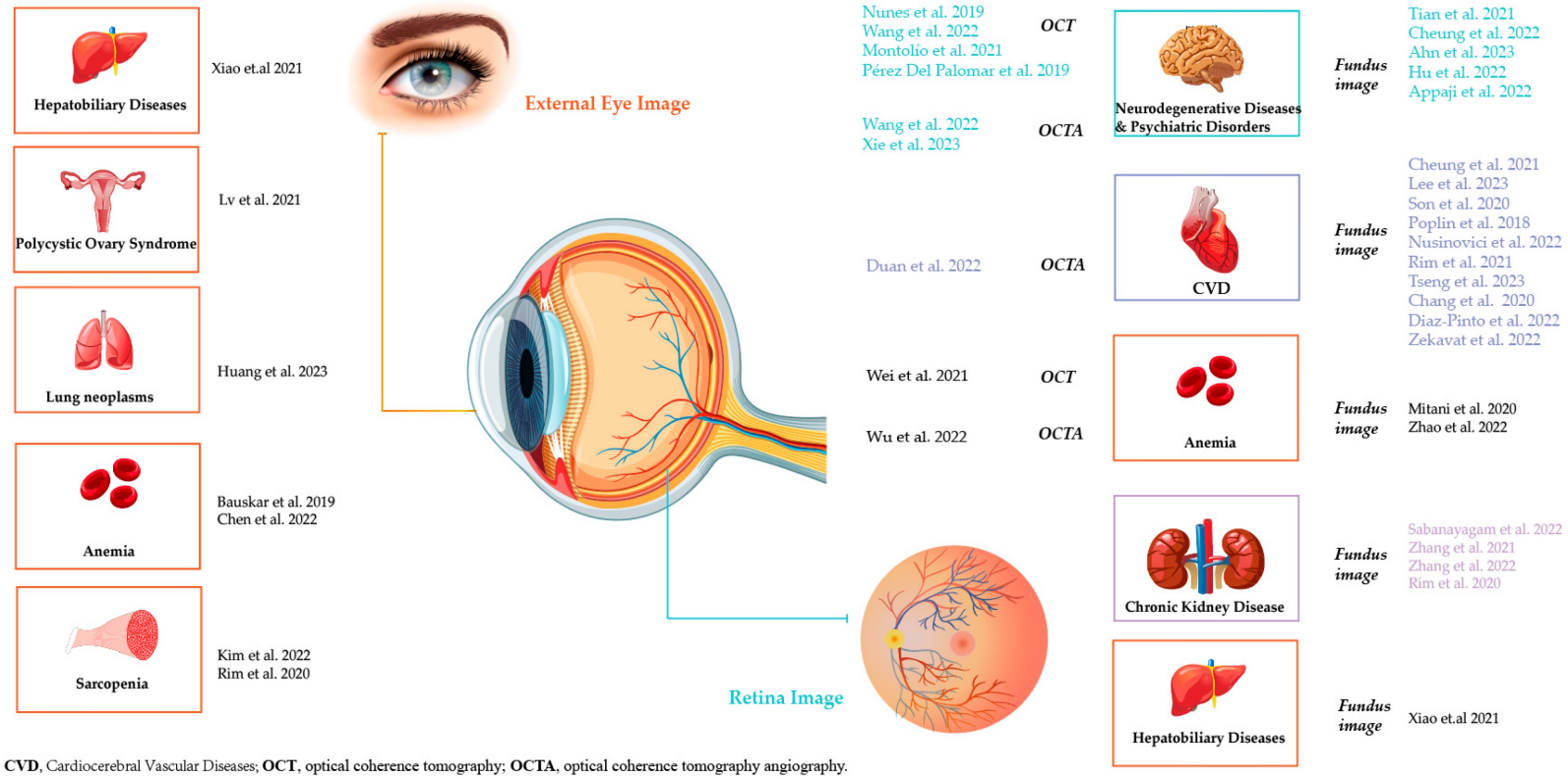

CVD, Cardiocerebral Vascular Diseases; **OCT**, optical coherence tomography; **OCTA**, optical coherence tomography angiography.

- artificial intelligence (AI) system that has the potential to not only identify sight-threatening eye diseases but also predict general health, including heart attacks, stroke, and Parkinson's disease.

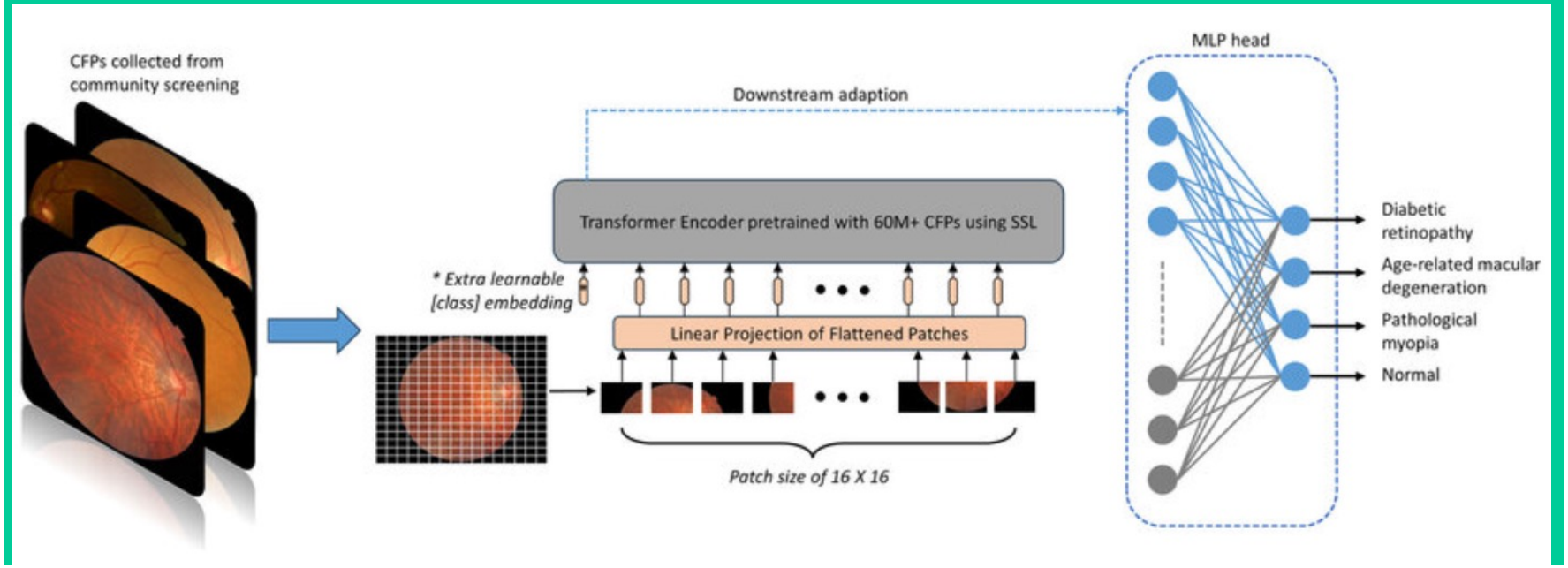

AI-integrated ocular imaging fo predicting cardiovascular disease

the ocular vasculature, particularly the retinal vasculature, has emerged as a potential means for Cardiovascular disease CVD risk stratification due to its anatomical similarities and physiological characteristics shared with other vital organs, such as the brain and heart.

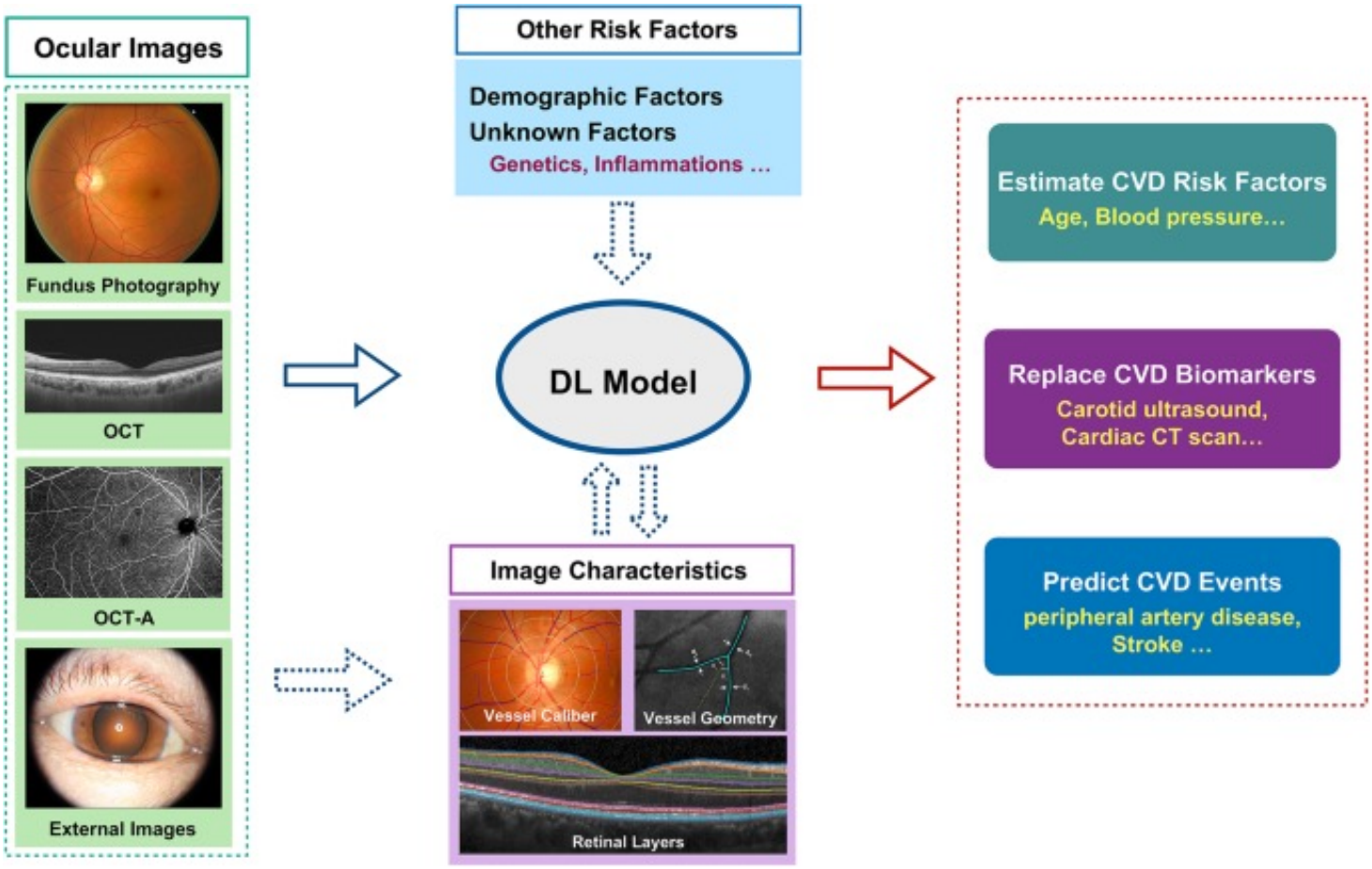

Eye **volume 38**, pages464–472 (2024)

Chronic kidney disease (CKD)

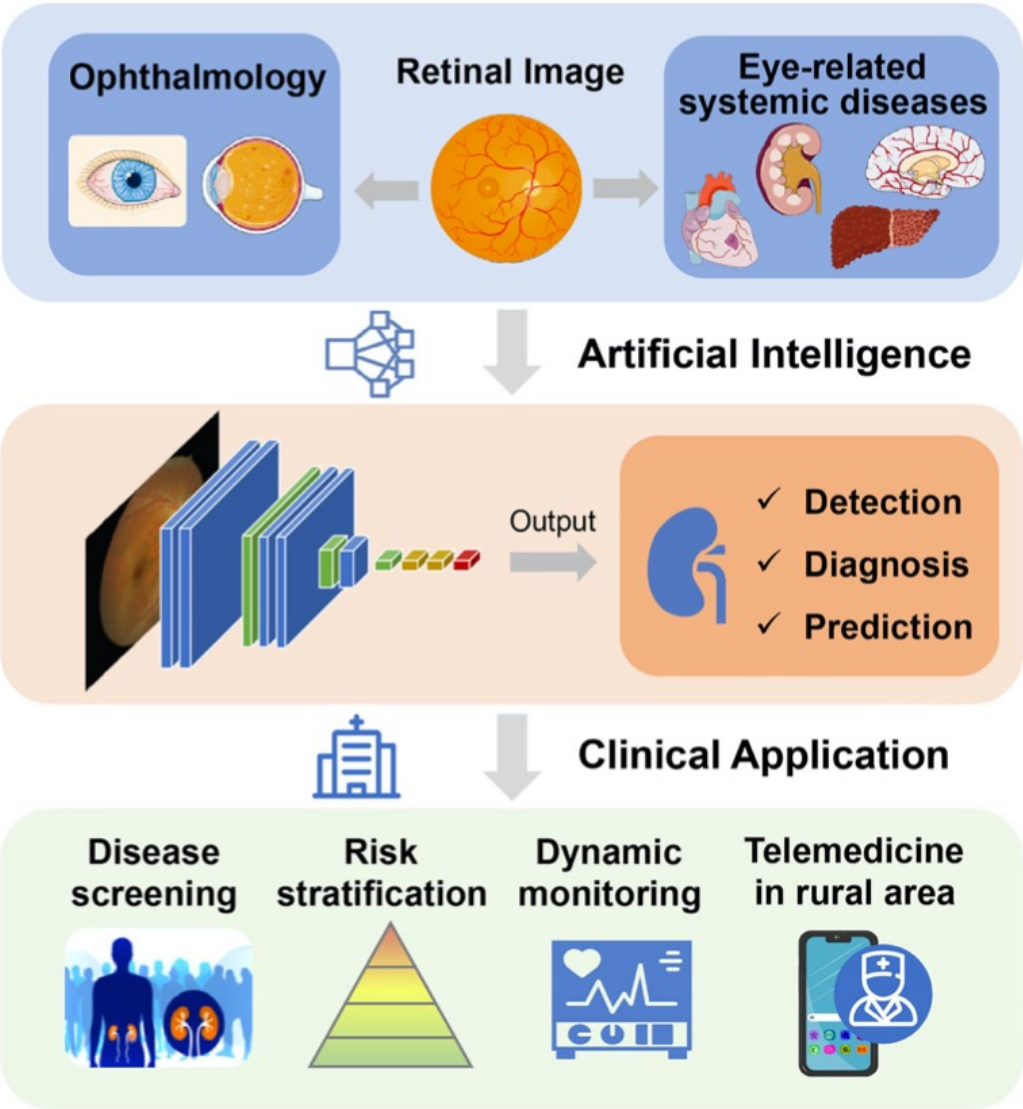

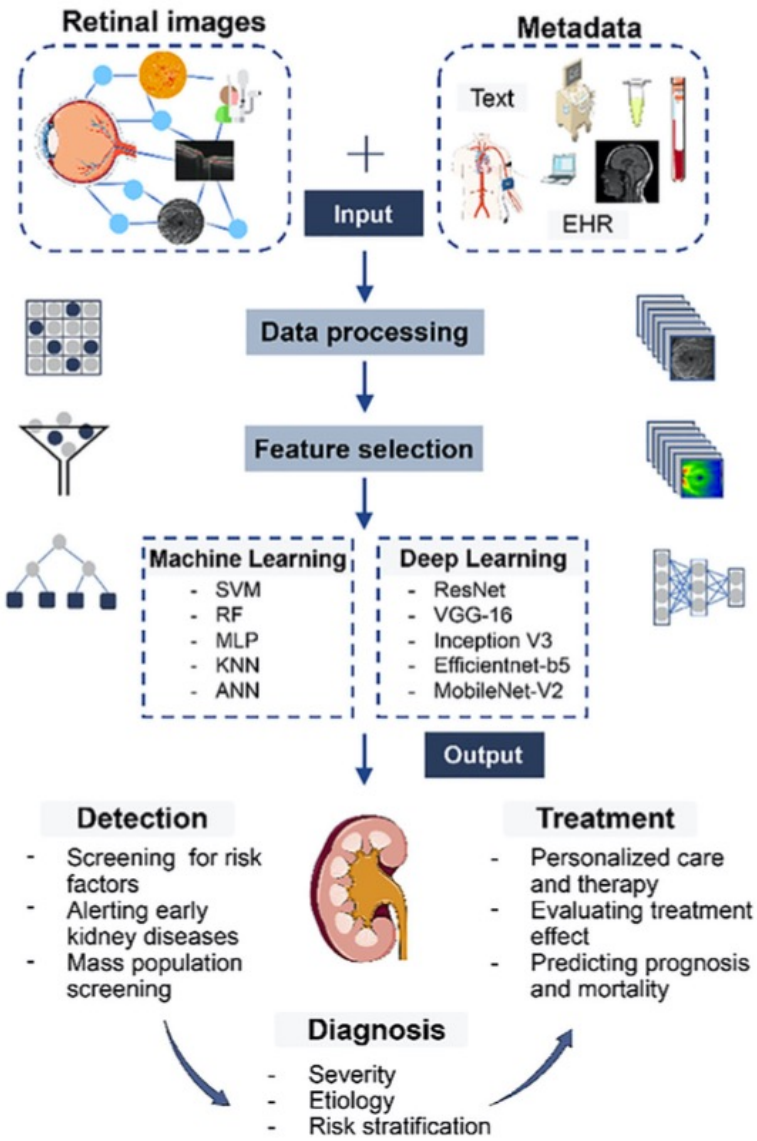

wileyonlinelibrary.com/journal/view

Chronic kidney disease (CKD)

- CKD and diabetes have manifestations in the retina, retinal images can be used to detect and monitor these diseases.

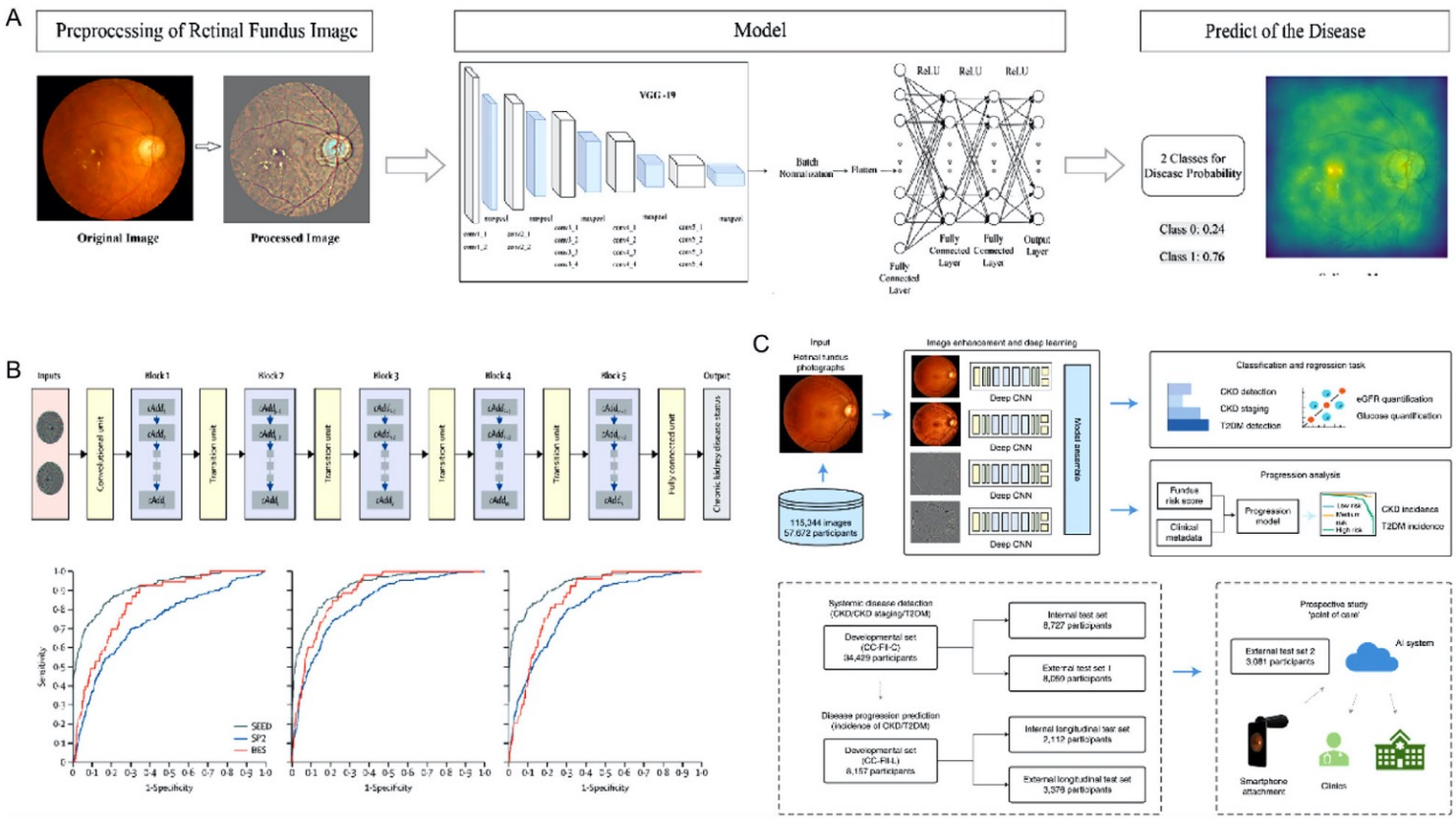

Alzheimer’s disease (AD)

- The retina is an extension of the central nervous system and offers a distinctively accessible insight into brain pathology.

Retina: a layer of photoreceptors cells and glial cells within the eye

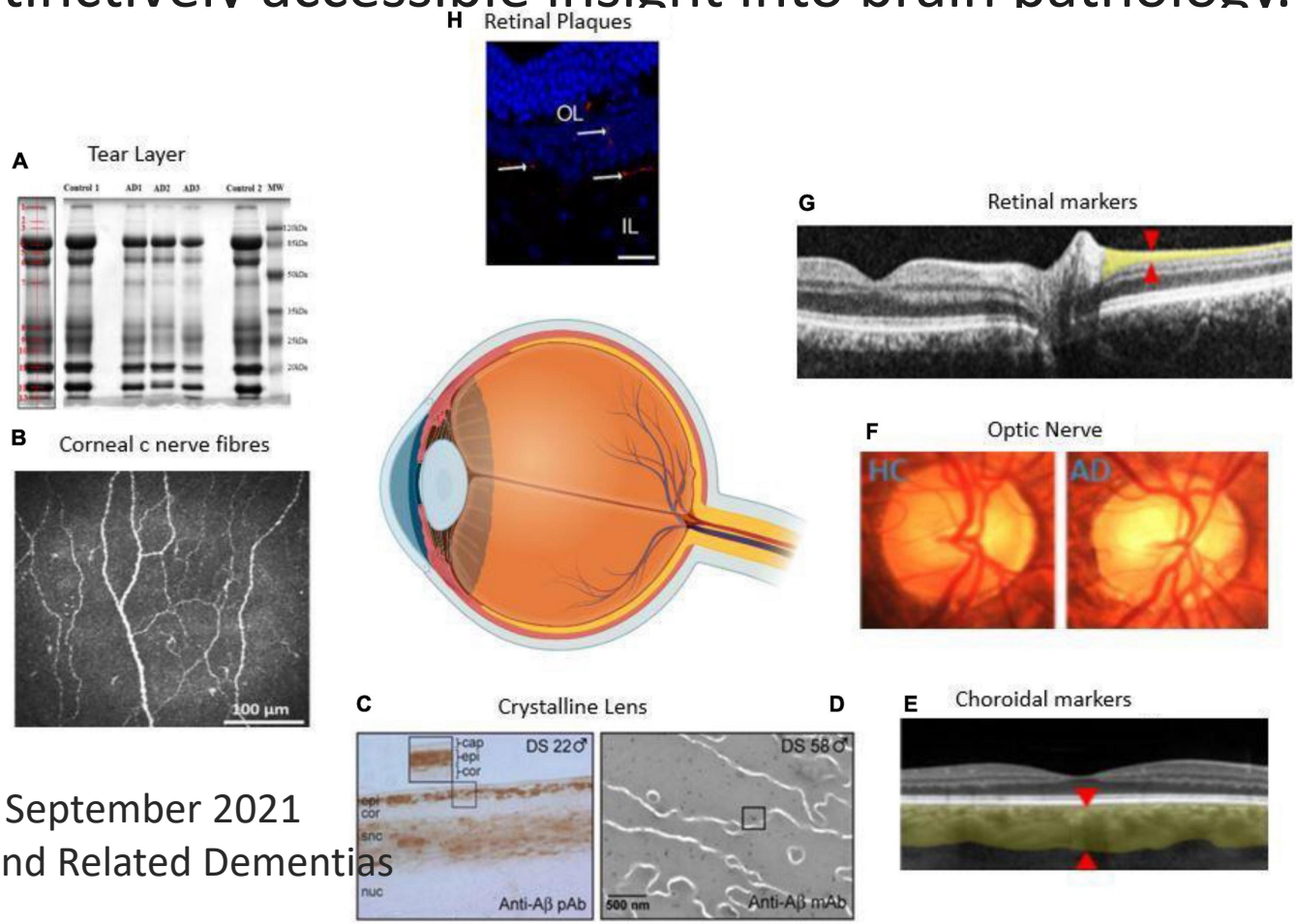

Front. Aging Neurosci., 10 September 2021
Sec. Alzheimer's Disease and Related Dementias
Volume 13 - 2021

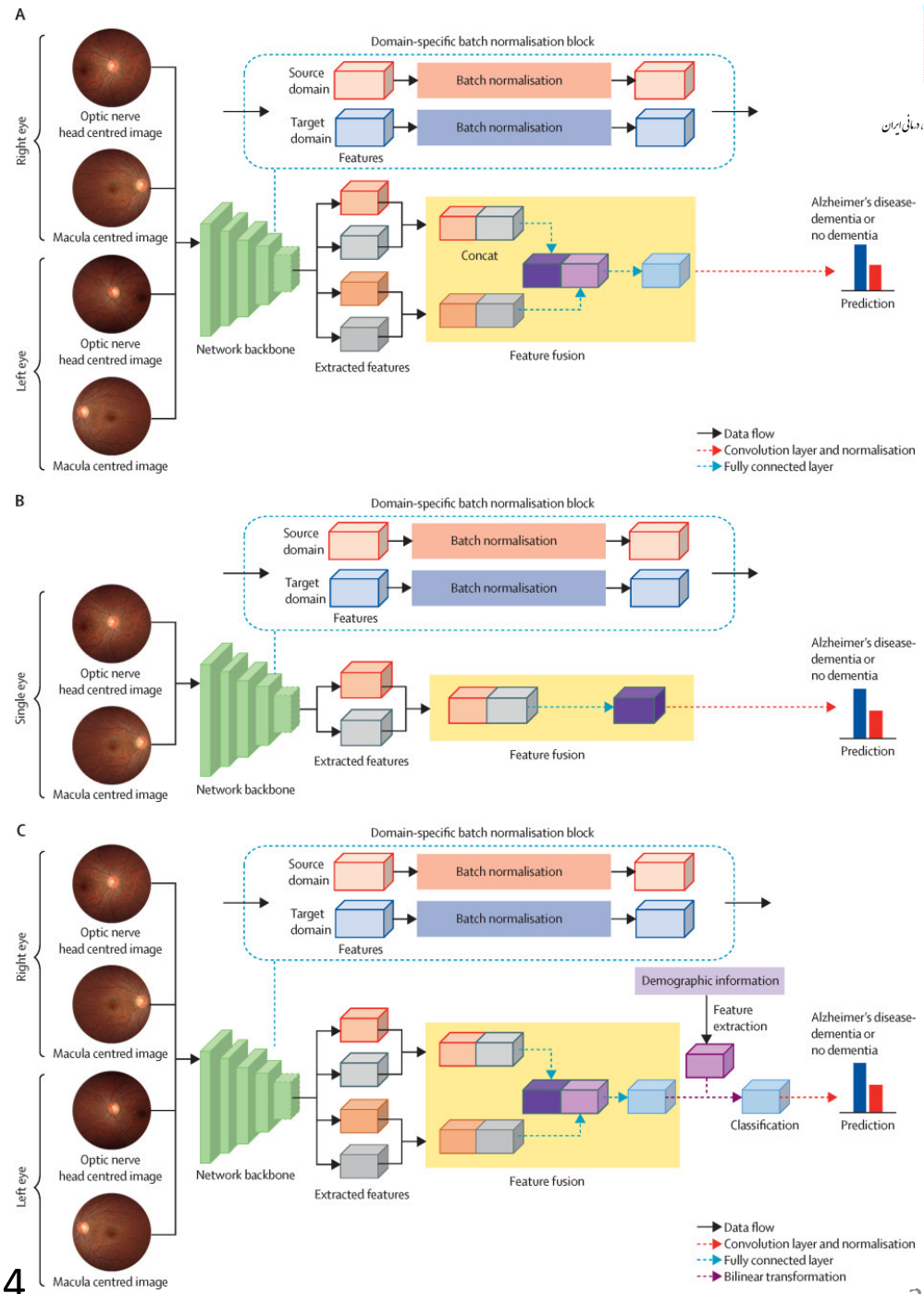

www.thelancet.com/digital-health Vol 4 November 2022

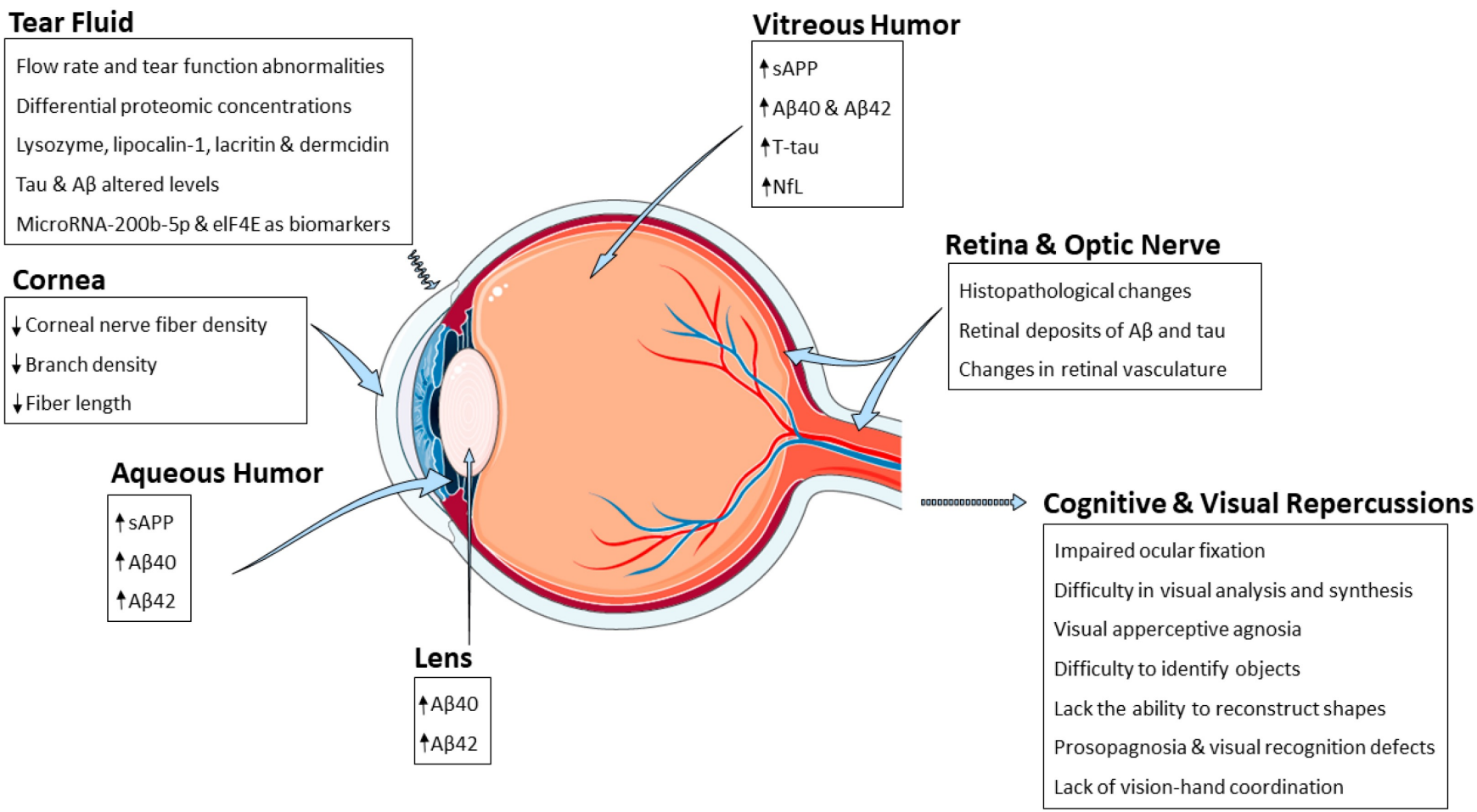
Tear Fluid
Flow rate and tear function abnormalities
Differential proteomic concentrations
Lysozyme, lipocalin-1, lacritin & dermcidin
Tau & Aβ altered levels
MicroRNA-200b-5p & eIF4E as biomarkers
Vitreous Humor
↑sAPP
↑Aβ40 & Aβ42
↑T-tau
↑NfL
Cornea
↓Corneal nerve fiber density
↓Branch density
↓Fiber length
Retina & Optic Nerve
Histopathological changes
Retinal deposits of Aβ and tau
Changes in retinal vasculature
Aqueous Humor
↑sAPP
↑Aβ40
↑Aβ42
Lens
↑Aβ40
↑Aβ42
Cognitive & Visual Repercussions
Impaired ocular fixation
Difficulty in visual analysis and synthesis
Visual apperceptive agnosia
Difficulty to identify objects
Lack the ability to reconstruct shapes
Prosopagnosia & visual recognition defects
Lack of vision-hand coordination

Data robustness

- Data sharing

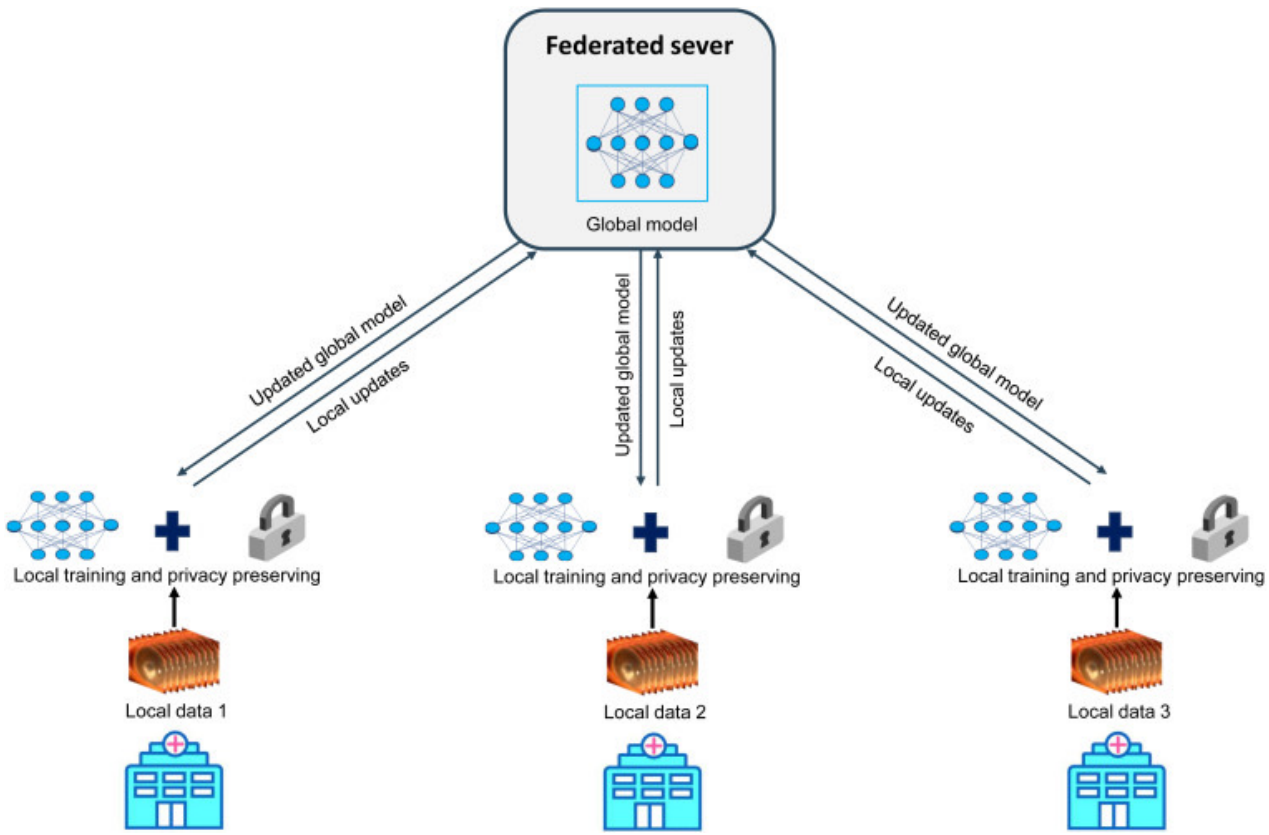

Data annotation

- Accurate clinical data annotations are crucial for the development of reliable AI systems.

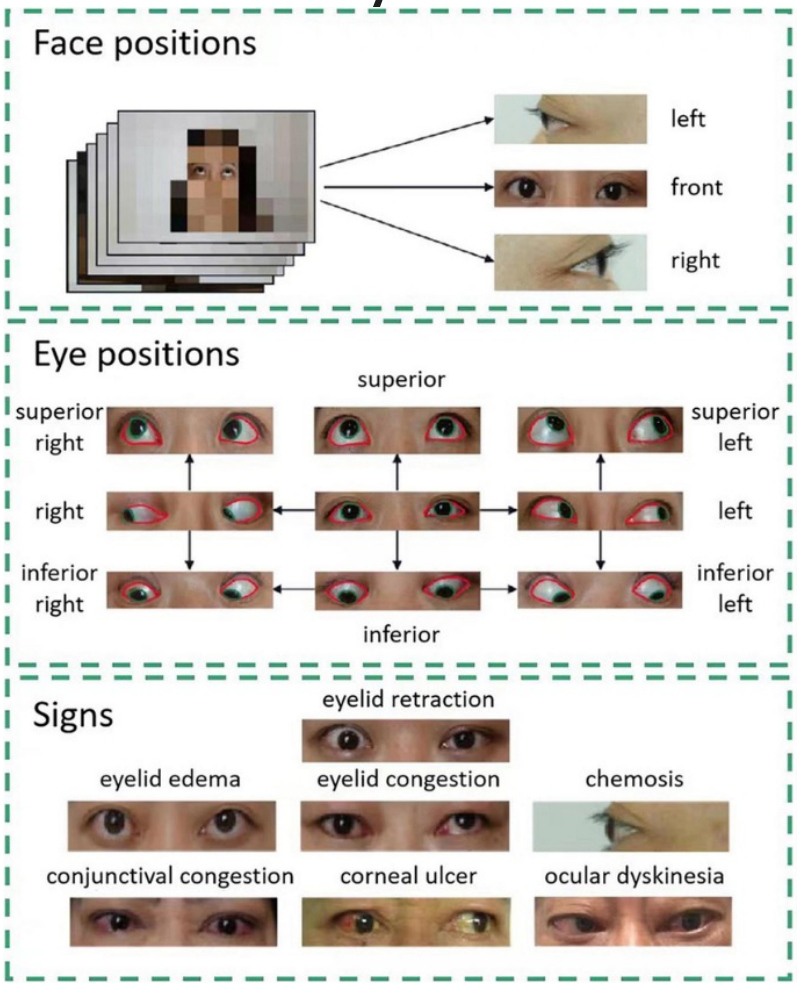

Artificial Intelligence in Predicting Systemic Parameters and Diseases From Ophthalmic Imaging

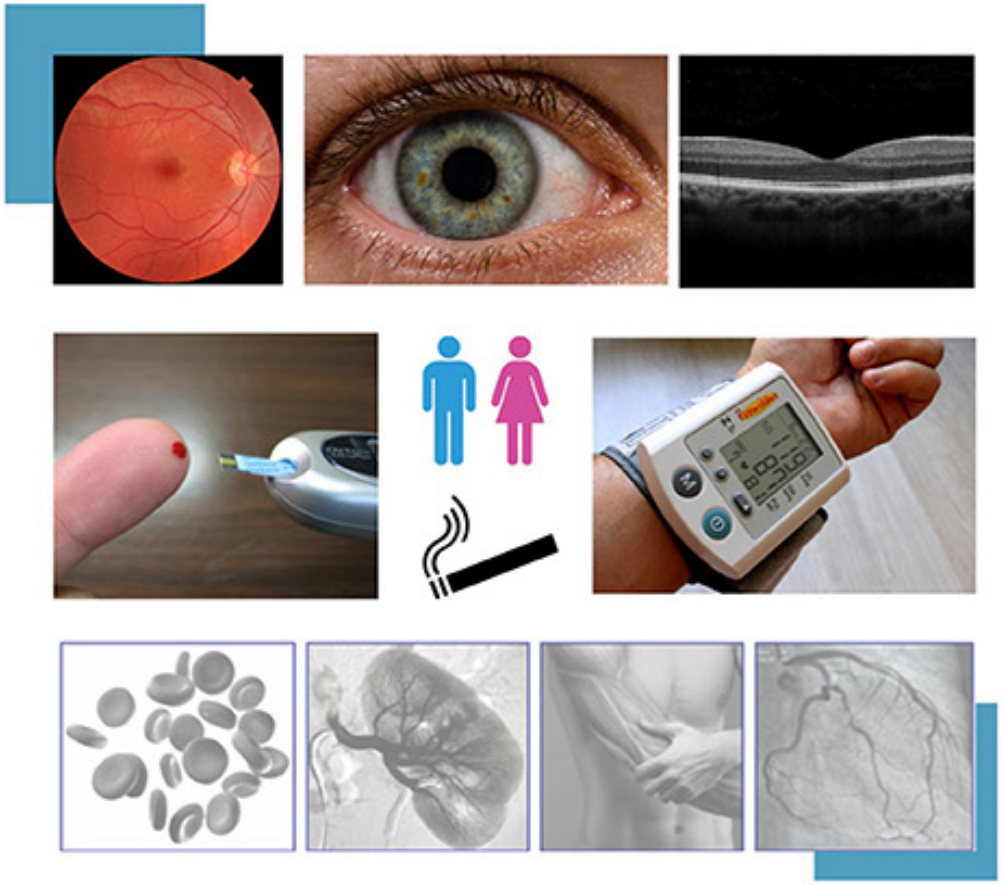

Predicting Markers of Systemic Disease through Ophthalmic Imaging

Smoking	Anemia
Atherosclerosis	RBC
Hematocrit	eGFR
Blood Pressure	Age
Hypertension	Gender
Diabetes	Weight
Creatinine	Height
CKD	BMI

Front. Digit. Health, 26 May 2022, Sec. Personalized Medicine, Volume 4 - 2022

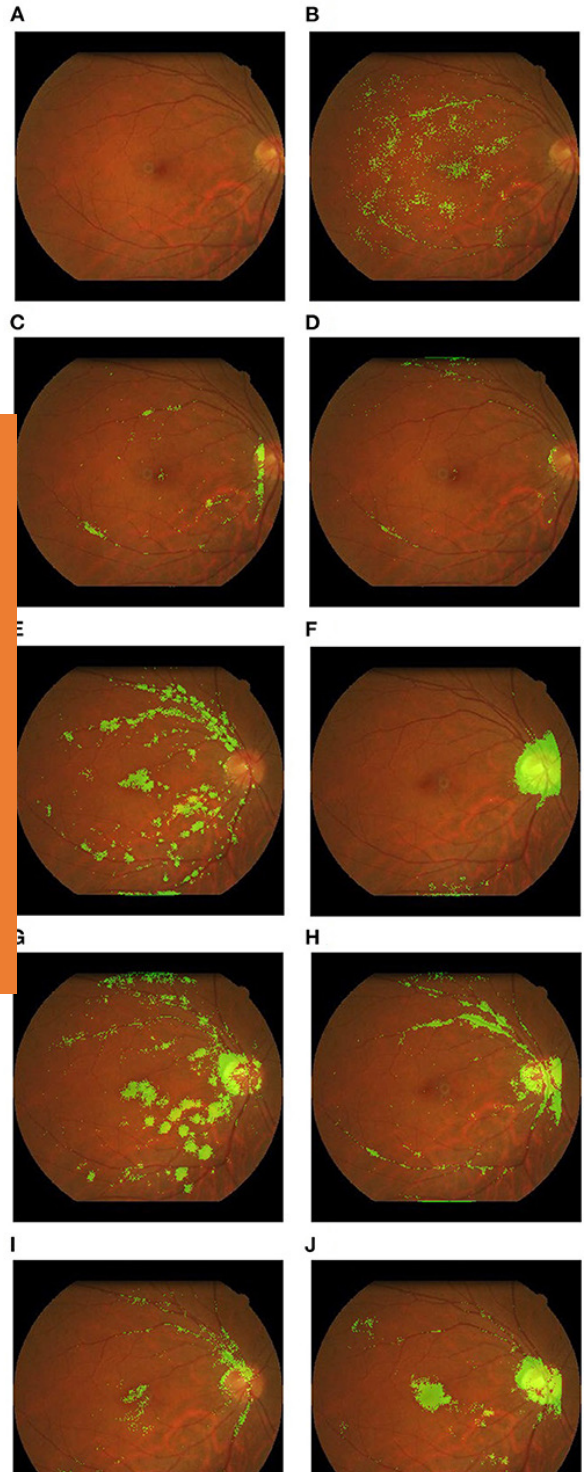

heatmaps overlaid on retinal fundus photographs highlighting areas of interest. These examples were derived from the authors' research database. **(A)** Original photograph with no overlay; **(B)** red blood cell count; **(C)** systolic blood pressure; **(D)** Weight; **(E)** age; **(F)** body mass index; **(G)** creatinine; **(H)** diastolic blood pressure; **(I)** hemoglobin; **(J)** height.

Performances of OCT or external eye imaging AI models in predicting systemic disease and parameters.

Imaging modality	Predicted parameter	AUC	95% CI	Sensitivity	95% CI	Specificity	95% CI	Accuracy	Study	Dataset	Internal/ External validation?
OCT	Alzheimer's disease			0.80		0.93		0.82	(35)	University of Coimbra, Portugal	Internal
OCT	Parkinson's disease			0.78		0.98		0.82	(35)	University of Coimbra, Portugal	Internal
OCT	Anemia*			0.82		0.82		0.84	(23)	Second Xiangya Hospital, China	Internal
OCT	Multiple sclerosis	0.97		0.89		0.92		0.91	(20)	Miguel Servet University Hospital, Spain	Internal
OCT	Multiple sclerosis	0.95	0.88–0.99						(26)	Miguel Servet University Hospital, Spain	Internal
OCT	Multiple sclerosis	0.99						0.972	(62)	Miguel Servet University Hospital, Spain	Internal
OCT B scans	Gender	0.84							(34)	University Clinic Bern, Switzerland	Internal
OCT C scans	Gender	0.90							(34)	University Clinic Bern, Switzerland	Internal
OCT-A	Diabetic status	0.80	0.73–0.87			0.49	0.31–0.69		(18)	Manchester Royal Eye Hospital	Internal
External eye images	Gender							0.94	(29)	Al-Azhar University, Cairo, Egypt	Internal
External eye images	HbA1c > 9%	0.70	0.69–0.71						(59)	EyePACS-–18 states	External
External eye images	HbA1c > 9%	0.73	0.72–0.75						(59)	EyePACS-–18 other states	External
External eye images	HbA1c > 9%	0.70	0.68–0.71						(59)	Atlanta veterans affairs	External
External eye images	HbA1c > 8%	0.69	0.68–0.70						(59)	EyePACS-–18 states	External
External eye images	HbA1c > 8%	0.74	0.73–0.76						(59)	EyePACS-–18 other states	External
External eye images	HbA1c > 8%	0.66	0.65–0.67						(59)	Atlanta veterans affairs	External
External eye images	HbA1c > 7%	0.67	0.66–0.68						(59)	EyePACS-–18 states	External
External eye images	HbA1c > 7%	0.74	0.73–0.76						(59)	EyePACS-–18 other states	External
External eye images	HbA1c > 7%	0.64	0.62–0.65						(59)	Atlanta veterans affairs	External
Infrared iris images	Diabetic status			0.99		0.97		0.90	(40)	Thapar University Patiala, India	Internal
Palpebral conjunctiva	Anemia < 11 g/dL†			0.78		0.83			(22)	Saint Mary's Hospital Luodong, Taiwan	Internal
Palpebral conjunctiva	Anemia < 11 g/dL‡			0.75		0.83			(22)	Saint Mary's Hospital Luodong, Taiwan	Internal
Palpebral conjunctiva	Anemia*			0.99		0.95		0.97	(27)	Bhopal, India	Internal
Slit lamp images	Cholelithiasis	0.58	0.55–0.61	0.57	0.46–0.68	0.58	0.55–0.61		(44)	Third Affiliated Hospital of Sun Yat-Sen University	Internal
Slit lamp images	Chronic viral hepatitis	0.69	0.66–0.71	0.55	0.45–0.65	0.78	0.76–0.81		(44)	Third Affiliated Hospital of Sun Yat-Sen University	Internal
Slit lamp images	Hepatic cyst	0.66	0.63–0.68	0.68	0.58–0.79	0.57	0.54–0.60		(44)	Third Affiliated Hospital of Sun Yat-Sen University	Internal
Slit lamp images	Hepatobiliary diseases	0.74	0.71–0.76	0.64	0.60–0.68	0.73	0.69–0.76		(44)	Third Affiliated Hospital of Sun Yat-Sen University	Internal
Slit lamp images	Liver cancer	0.93	0.91–0.94	0.89	0.79–0.99	0.89	0.87–0.91		(44)	Third Affiliated Hospital of Sun Yat-Sen University	Internal
Slit lamp images	Liver cirrhosis	0.90	0.88–0.91	0.78	0.66–0.90	0.91	0.89–0.92		(44)	Third Affiliated Hospital of Sun Yat-Sen University	Internal
Slit lamp images	NAFLD	0.63	0.60–0.66	0.69	0.64–0.74	0.53	0.50–0.57		(44)	Third Affiliated Hospital of Sun Yat-Sen University	Internal

AUC, area under the receiver operating curve; CI, confidence interval; HbA1c, Hemoglobin A1c; NAFLD, non-alcoholic fatty liver disease; OCT, optical coherence tomography; OCT-A, optical coherence tomography angiography.
**Chen et al. (23) and Jain et al. (27) did not describe how anemia was defined.*
†Chen et al. (22) constructed a SVM model and CNN model. This row represents the SVM.
‡Chen et al. (22) constructed a SVM model and CNN model. This row represents the CNN.
None of the studies in this table reported R^2-values as a performance metric, or 95% CI for Accuracy.

Artificial intelligence to detect malignant eyelid tumors from photographic images

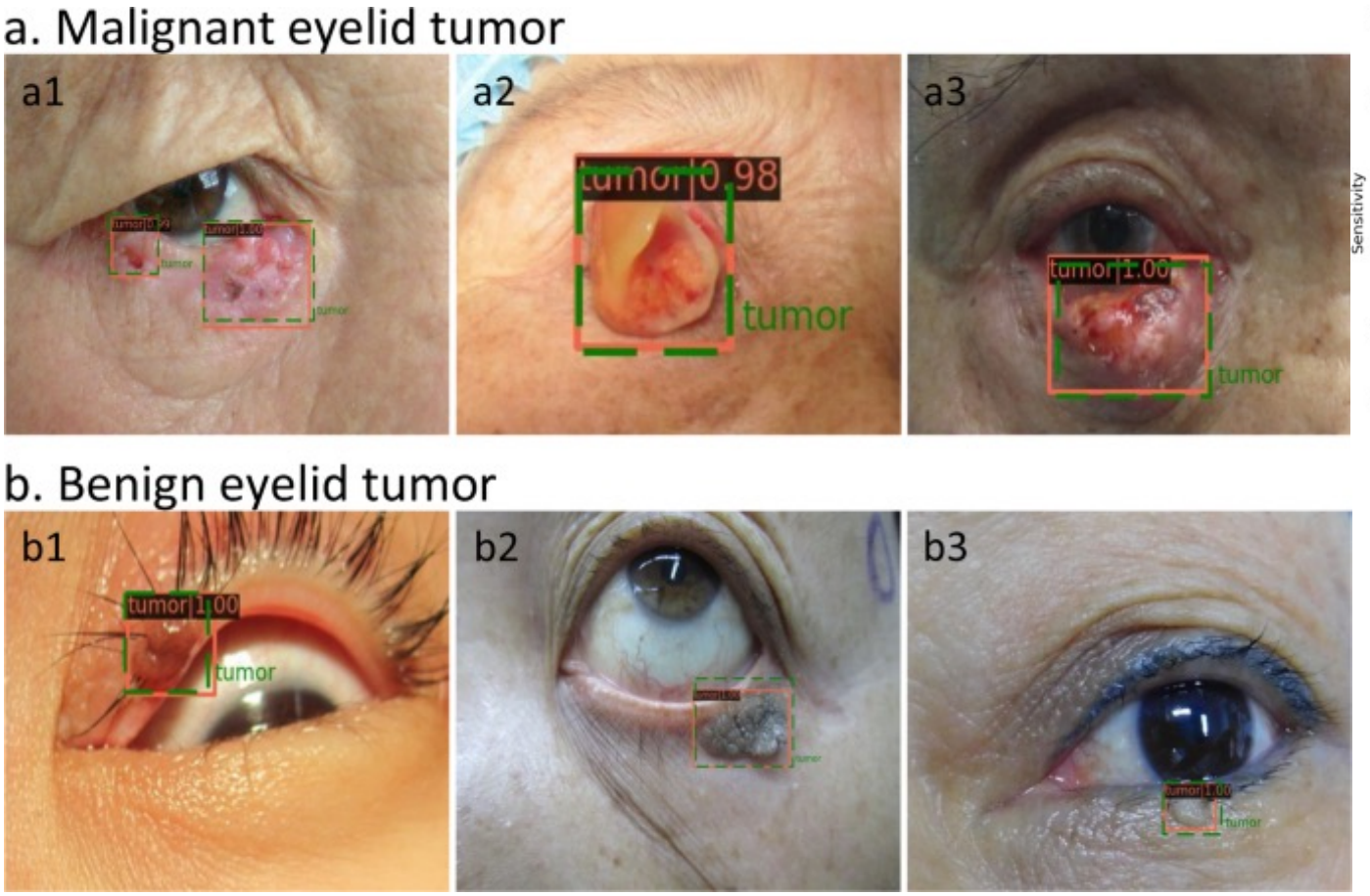

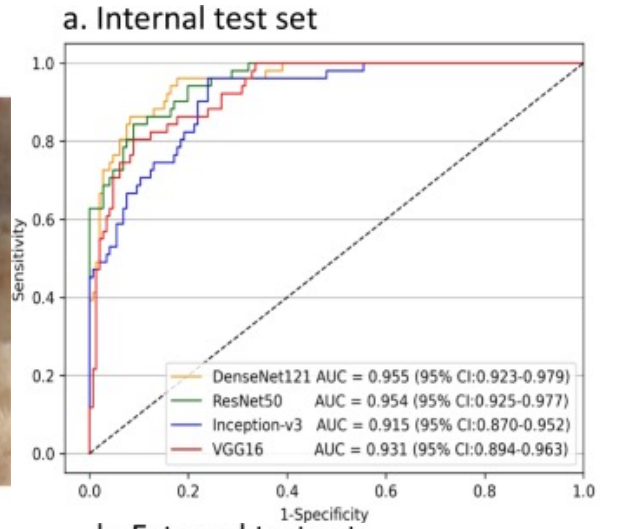

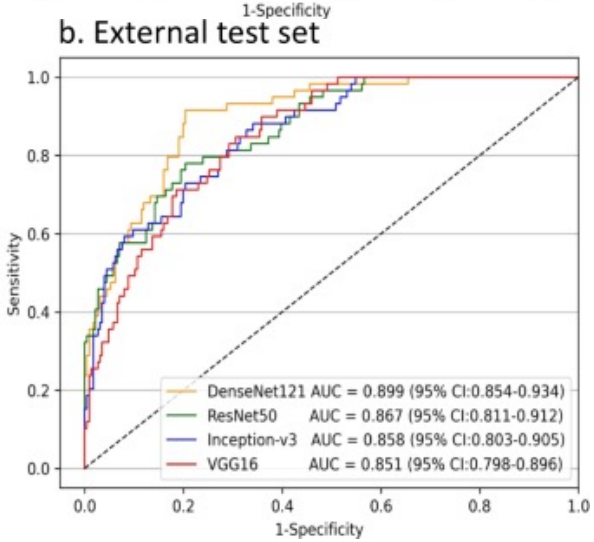

npj Digital Medicine **volume 5**, Article number: 23 (2022)

A foundation model for generalizable disease detection from retinal images

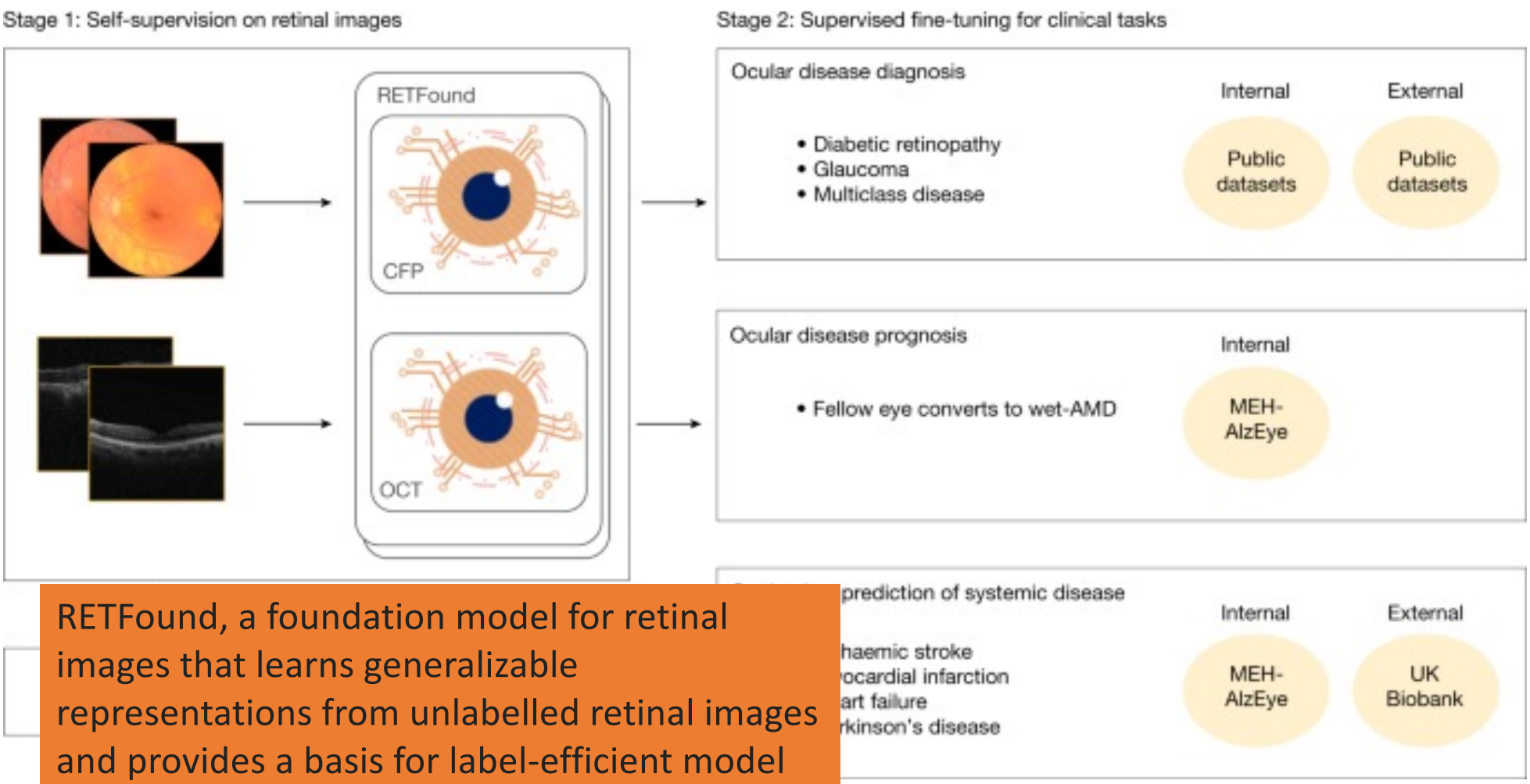

RETFound, a foundation model for retinal images that learns generalizable representations from unlabelled retinal images and provides a basis for label-efficient model adaptation in several applications.

Nature **volume 622**, pages156–163 (2023)

Clinically applicable deep learning for

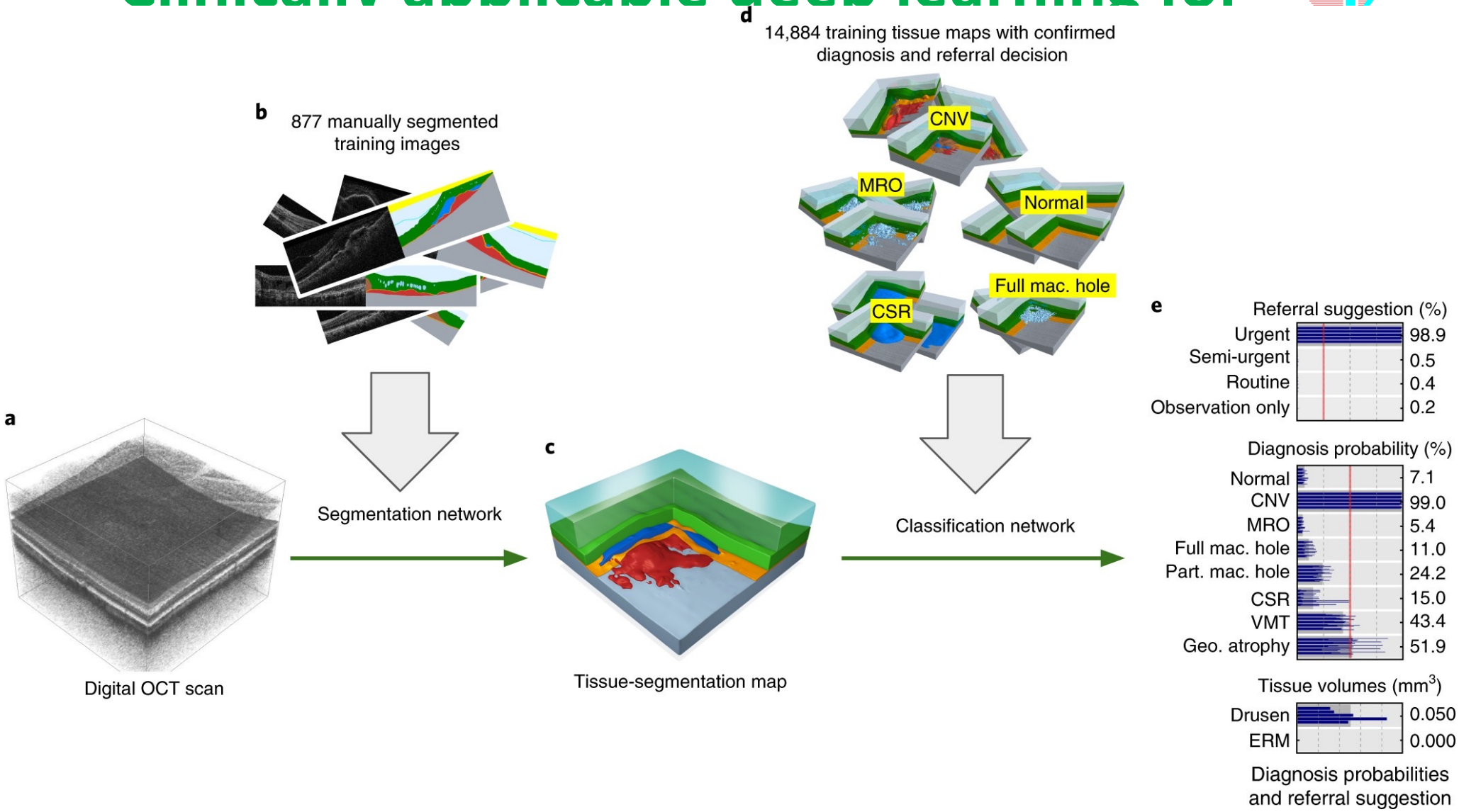

Nature Medicine **volume 24**, pages1342–1350 (2018)

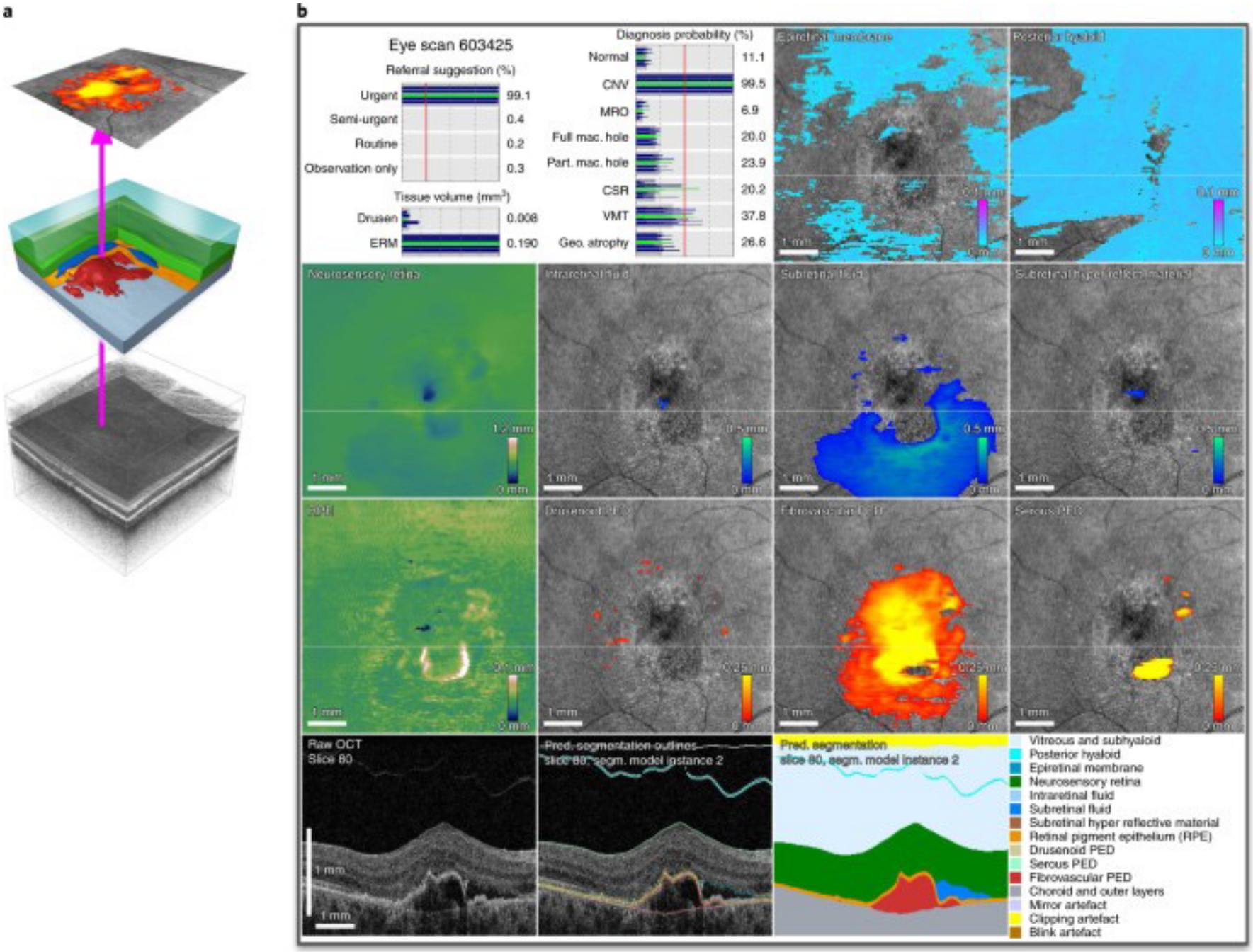
a
b
Eye scan 603425
Referral suggestion (%)
Urgent 99.1
Semi-urgent 0.4
Routine 0.2
Observation only 0.3
Tissue volume (mm³)
Drusen 0.008
ERM 0.190
Diagnosis probability (%)
Normal 11.1
CNV 99.5
MRO 6.9
Full mac. hole 20.0
Part. mac. hole 23.9
CSR 20.2
VMT 37.8
Geo. atrophy 26.6
Raw OCT
Slice 80
Pred. segmentation
slice 80, segm. model instance 2
Vitreous and subhyaloid
Posterior hyaloid
Epiretinal membrane
Neurosensory retina
Intraretinal fluid
Subretinal fluid
Subretinal hyper reflective material
Retinal pigment epithelium (RPE)
Drusenoid PED
Serous PED
Fibrovascular PED
Choroid and outer layers
Mirror artefact
Clipping artefact
Blink artefact

Artificial intelligence chatbot interpretation of ophthalmic multimodal imaging cases

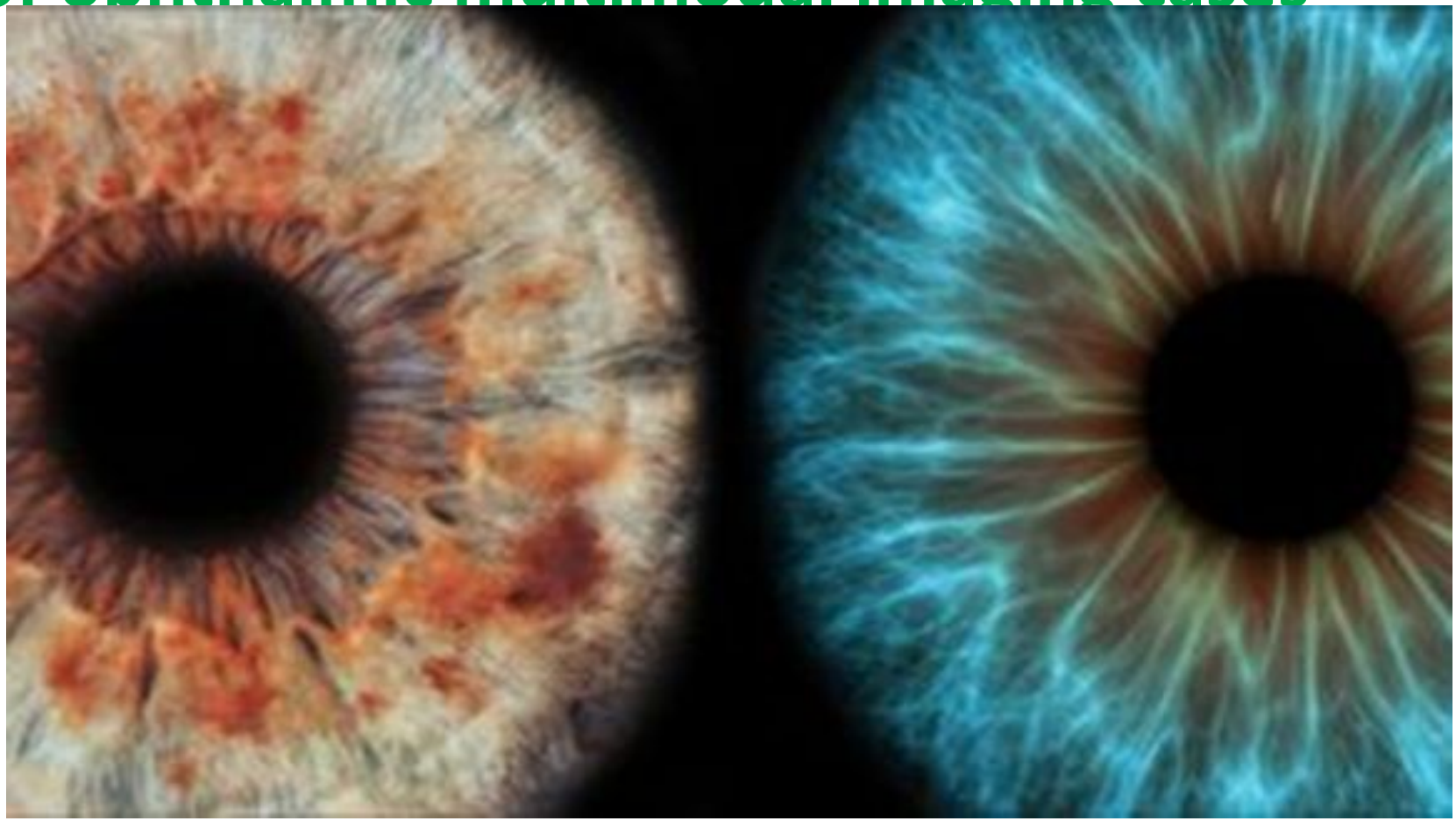

Eye (2024)

OpenAI's Sora in ophthalmology: revolutionary generative AI in eye health

The technological foundation of Sora rests on Large Language Models (LLMs) and artificial video generation techniques.

Surgical training
Ophthalmic surgery is a highly technical and learning new surgical techniques can be time intensive. Sora can be used to generate step-by-step surgical technique videos from text descriptions.

Patient Education
Strong ophthalmologist-patient communication is essential in the management of eye disease. Helping to educate and empower patients with conditions such as glaucoma, has been shown to improve both clinical outcomes [7] and treatment adherence

Eye (2024)

دانشگاه علوم پزشکی و خدمات بهداشتی، درمانی ایران

Public awareness campaigns
To reduce preventable blindness and vision impairments, the general public must be aware of the importance of regular eye examinations.

Clinician education
A video generated by Sora can potentially illustrate symptoms and signs of rare/uncommon ophthalmic diseases, to help improve the ability of ophthalmologists-in-training to recognize them. Ophthalmology residents could then observe and diagnose these conditions in a supportive and controlled environment.

Large language models in vitreoretinal surgery

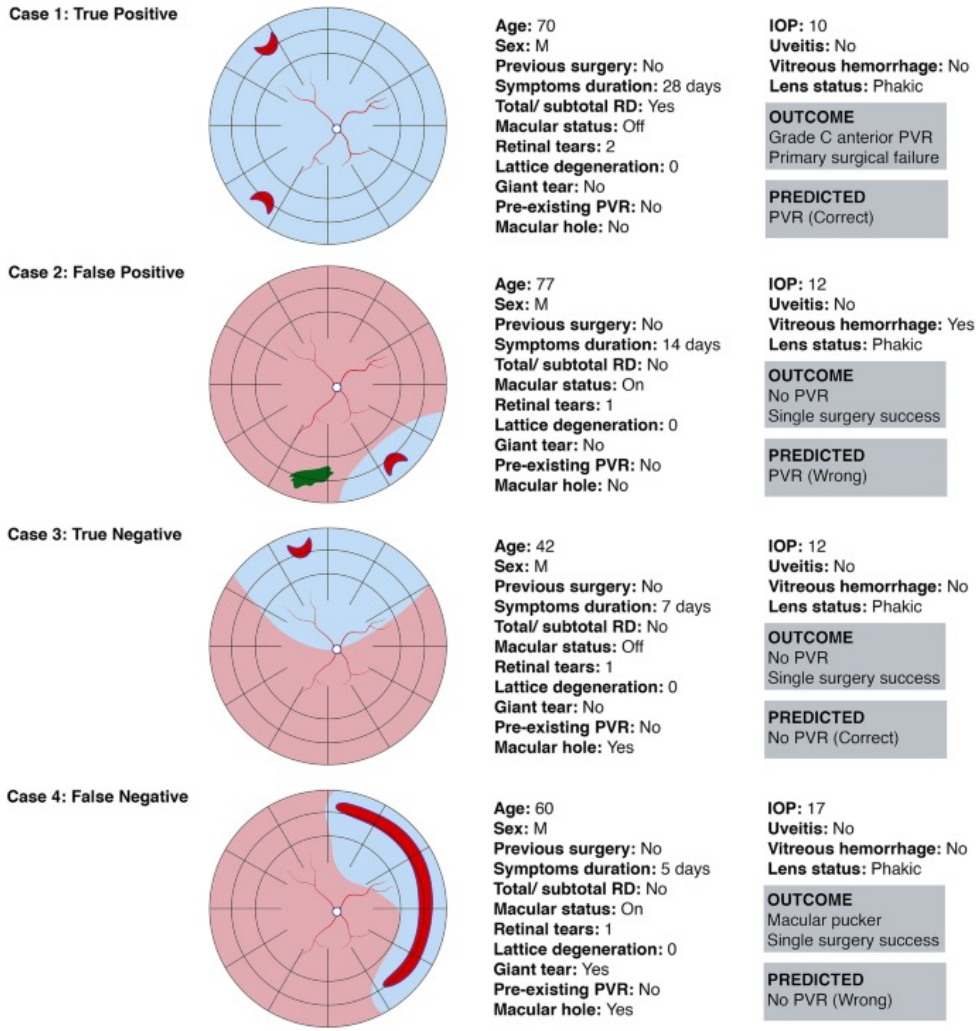

Eye **volume 38**, pages809–810 (2024)

GPT-4 to document ophthalmic post-operative complications

ChatGPT, created by OpenAI, is an advanced AI chatbot that utilizes the GPT-4 (Generative Pre-trained Transformer 4) large language model. Large language models (LLMs) have been developed to produce responses that resemble human language in response to inputs in natural language

Eye **volume 38**, pages414–415 (2024)

Potential of ChatGPT in ophthalmology.

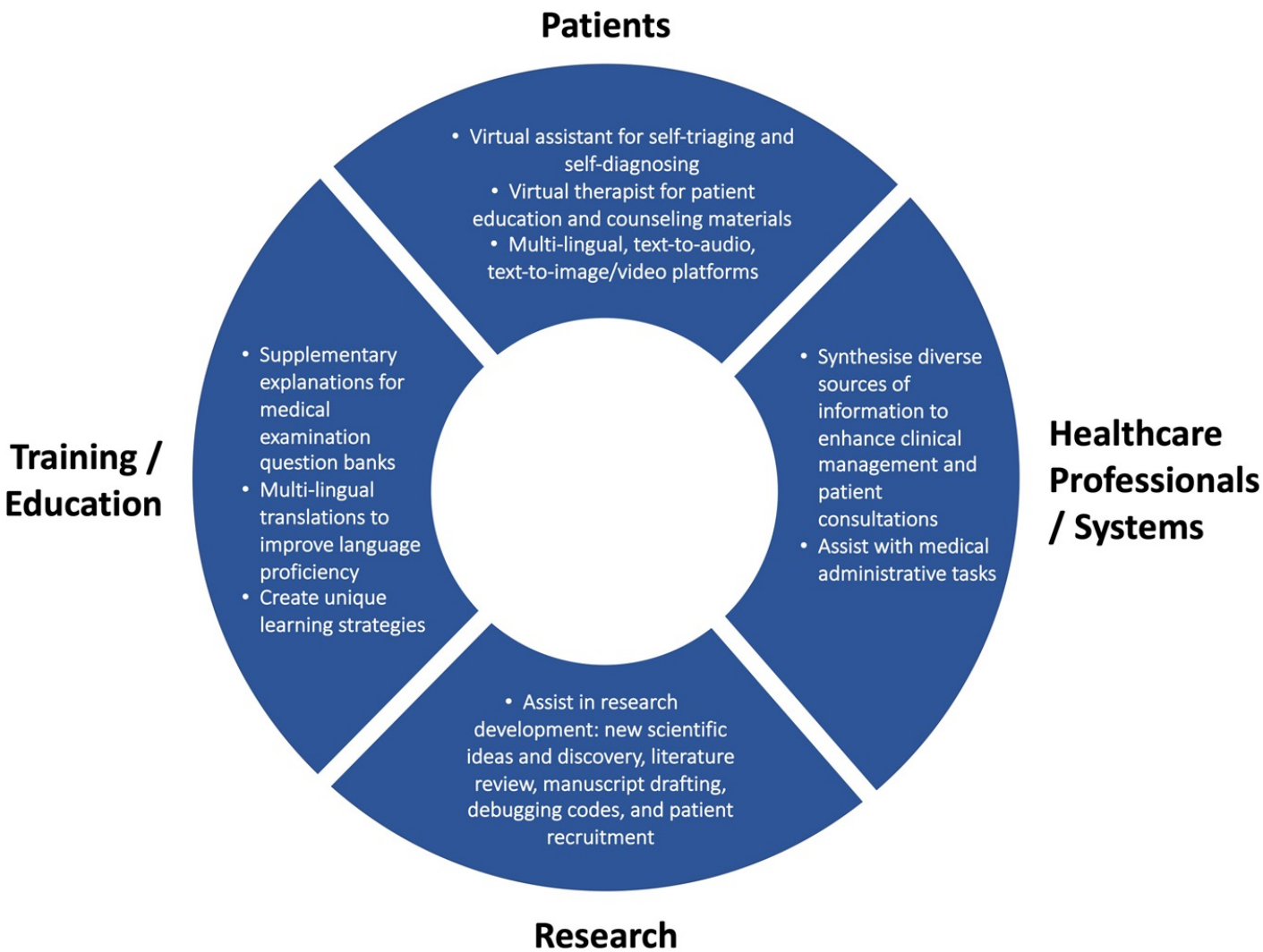

Eye **volume 38**, pages4–7 (2024)

A My eye has suddenly become red but there is no pain or loss of vision. I am currently taking warfarin and some other tablets for my high blood pressure. Do I need to be worried?

While I'm an AI and can't diagnose or provide medical advice, I can tell you that sudden redness in the eye can have many causes. It could be something as simple as a burst blood vessel, known as a subconjunctival hemorrhage, which can occur spontaneously or due to minor trauma, coughing, or straining. It's often benign and resolves on its own. Taking blood thinners like warfarin can make this more likely to occur.

However, it's also possible that the redness is due to more serious conditions like glaucoma, uveitis, or an infection.

Since you have high blood pressure and are on blood thinners, it's important to take any changes to your eye health seriously. Even though you're not experiencing pain or vision loss, it would be a good idea to contact your healthcare provider or an eye specialist (ophthalmologist) to discuss your symptoms. They can guide you on whether you need an in-person examination and help rule out any potential serious causes.

B I am having a severe painful eye with light sensitivity, loss of vision and headache. What is wrong with my eye and do I need to see an ophthalmologist?

These symptoms could be indicative of several serious eye conditions, including acute angle-closure glaucoma, uveitis, corneal abrasion or ulcer, or optic neuritis, among others.

Acute angle-closure glaucoma, in particular, is a medical emergency. It occurs when the drainage canals in your eye become blocked, causing a rapid rise in intraocular pressure. Symptoms can include severe eye pain, nausea, redness in your eye, blurred vision, and headache.

Given the severity of your symptoms - especially the severe pain, light sensitivity, and vision loss - you should seek immediate medical attention. Please contact your healthcare provider or go to an emergency room right away. Do not delay. An ophthalmologist should be involved in your care as soon as possible.

Remember, while I can provide information based on the symptoms you've described, only a healthcare professional can make an accurate diagnosis and guide your treatment. Please seek medical attention immediately.

C Can you explain to me about cataract surgery?

Certainly. Cataract surgery is a procedure performed to treat cataracts, a condition where the lens of your eye becomes clouded, leading to a decrease in vision. This clouding is typically due to aging, but can also occur for other reasons like trauma, certain medical conditions, or medications.

Cataract surgery involves removing the clouded lens and replacing it with a clear artificial lens. Here's a general outline of the process:

1. **Preparation:** Prior to surgery, your eye will be measured to determine the proper power for your intraocular lens (IOL). You may be advised to temporarily stop certain medications. On the day of surgery, you'll likely be asked to fast for a few hours before the procedure.
2. **Anesthesia:** Before the procedure begins, you'll be given local anesthesia to numb your eye. This is often combined with a sedative to help you relax.
3. **Procedure:** The surgeon will make a small incision in the cornea, the clear, domed surface of your eye. Through this incision, a small instrument uses ultrasound waves to break up the lens into small pieces, which are then suctioned out (this is called phacoemulsification). Once the clouded lens is removed, the artificial lens (IOL) is inserted through the same incision and positioned correctly. In most cases, the incision is self-sealing and doesn't require stitches.
4. **Post-Operative Care:** After surgery, you may wear an eye patch or protective shield for a few hours or overnight. You'll be prescribed eye drops to prevent infection and inflammation. Complete recovery often takes about a month, during which you'll need to avoid strenuous activities.

The procedure is generally safe and effective, with most people achieving improved vision. However, as with any surgery, there are potential risks, including infection, inflammation, bleeding, swelling, retinal detachment, glaucoma, and secondary cataract. Sometimes, people might still need to wear glasses or contact lenses after cataract surgery for the best vision.

Always discuss with your ophthalmologist to fully understand the procedure, its risks and benefits, and what to expect during recovery.

D How should I treat optic neuritis?

Optic neuritis is an inflammation that damages the optic nerve, a bundle of nerve fibers that transmits visual information from your eye to your brain. Common symptoms may include pain with eye movement and temporary vision loss.

Treatment for optic neuritis depends on the cause. When it's associated with multiple sclerosis or another autoimmune disease, treatment might involve managing the underlying condition.

Here are some common treatment methods:

1. **Corticosteroids**: This is the primary treatment for optic neuritis. Corticosteroids can help reduce inflammation and speed up recovery of vision. These are typically given intravenously (IV) for several days, followed by a tapering dose of oral steroids. Steroids may also decrease the risk of developing multiple sclerosis or delay its onset.
2. **Plasma exchange therapy (plasmapheresis)**: This might be used if symptoms are severe and you don't respond to steroid treatment. In this procedure, plasma — the liquid part of your blood — is removed and separated from your blood cells. The blood cells are then mixed with a replacement solution and returned to your body.
3. **Immunomodulatory drugs**: If optic neuritis is related to multiple sclerosis or neuromyelitis optica (a chronic disorder of the nerves and the brain), long-term immunomodulatory therapy might be recommended to prevent recurrences.
4. **Symptomatic treatment**: Pain relievers can help manage the discomfort that often comes with optic neuritis.

However, it's important to note that in many cases, optic neuritis improves on its own, without treatment. Some studies suggest that while corticosteroids speed up recovery, they don't appear to affect the degree of recovery.

It's crucial to get a professional diagnosis and personalized treatment plan from your healthcare provider or ophthalmologist. Regular follow-ups are necessary to monitor the disease's progression and adjust treatment as necessary.

E Can you generate some ophthalmology-related questions to examine the knowledge of an ophthalmologist to ensure safe practice?

Absolutely, here are some questions that could be used to assess the knowledge of an ophthalmologist:

1. Can you explain the pathophysiology of primary open-angle glaucoma?
2. What are the common causes of uveitis and how would you approach a differential diagnosis?
3. What is the normal intraocular pressure range and what factors can influence it?
4. How does the Amsler grid test work and what conditions is it useful in diagnosing?
5. Please describe the differences between macular degeneration and diabetic retinopathy.
6. What are the primary symptoms of retinal detachment and what immediate actions would you recommend if a patient presents with these symptoms?
7. Could you explain the role of vascular endothelial growth factor (VEGF) in ocular neovascularization and the therapeutic approaches targeting it?
8. How do you manage ocular trauma, specifically hyphema and globe rupture?
9. Can you describe the typical progression and treatment options for keratoconus?
10. What are the key features of Fuchs' dystrophy and how is it managed?
11. Describe the steps you would take to diagnose and manage a patient with chronic dry eye syndrome.
12. Can you explain the mechanism of action and the side effects of common topical glaucoma medications?
13. What are the common complications of cataract surgery and how do you manage them?
14. How do you approach a pediatric patient with strabismus?
15. What are the contraindications for LASIK surgery and what alternative procedures would you recommend for those patients?
16. Can you describe the visual field defects associated with glaucoma and pituitary adenomas?

GPT-4 for triaging ophthalmic symptoms

Red (Less Than 10 Minutes)	Green (Less Than 60 Minutes)	Blue (Waiting for Availability)
1.Penetrating injury	1.Corneal abrasion	1.Painless diplopia
2.Chemical burn	2.Corneal /conjunctiva, foreign body	2.Flashes and floaters
3.Headache, sudden loss of visual acuity, elderly, giant cell arthritis	3.Orbital cellulites	3.Recent non-specific blurred vision
4.Painful third cranial nerve palsy, diplopia	4.Infectious conditions, adenovirus	4.Non-specific eye pain
5.Acute glaucoma	5.Corneal ulcer, abscess	5.Conjunctivitis
6.Crying babies with cloudy cornea	6.Welding flash	6.Trichiasis
7.Hypopyon	7.Retinal detachment	7.Cysts (except in children)
8.Severe eye pain	8.Hyphema	8.Phlyctenulosis
9.Intraocular foreign body	9.Recent surgery with complications	9.Blepharitis

Note: White code for none-eye emergencies.

Eye **volume 37**, pages3874–3875 (2023)

Comparative analysis of large language models in the Royal College of Ophthalmologists fellowship exams

- Large language models (LLMs) have become a popular area of research in this field, and have been integrated into publicly available chatbots such as ChatGPT 3.5 and 4.0 (*OpenAI*, CA, US), Google Bard (*Alphabet Inc*., CA, US), and Bing Chat (*Microsoft Corporation*, WA, US)

Correlation between AI-measured lacquer cracks extension and development of myopic choroidal neovascularization

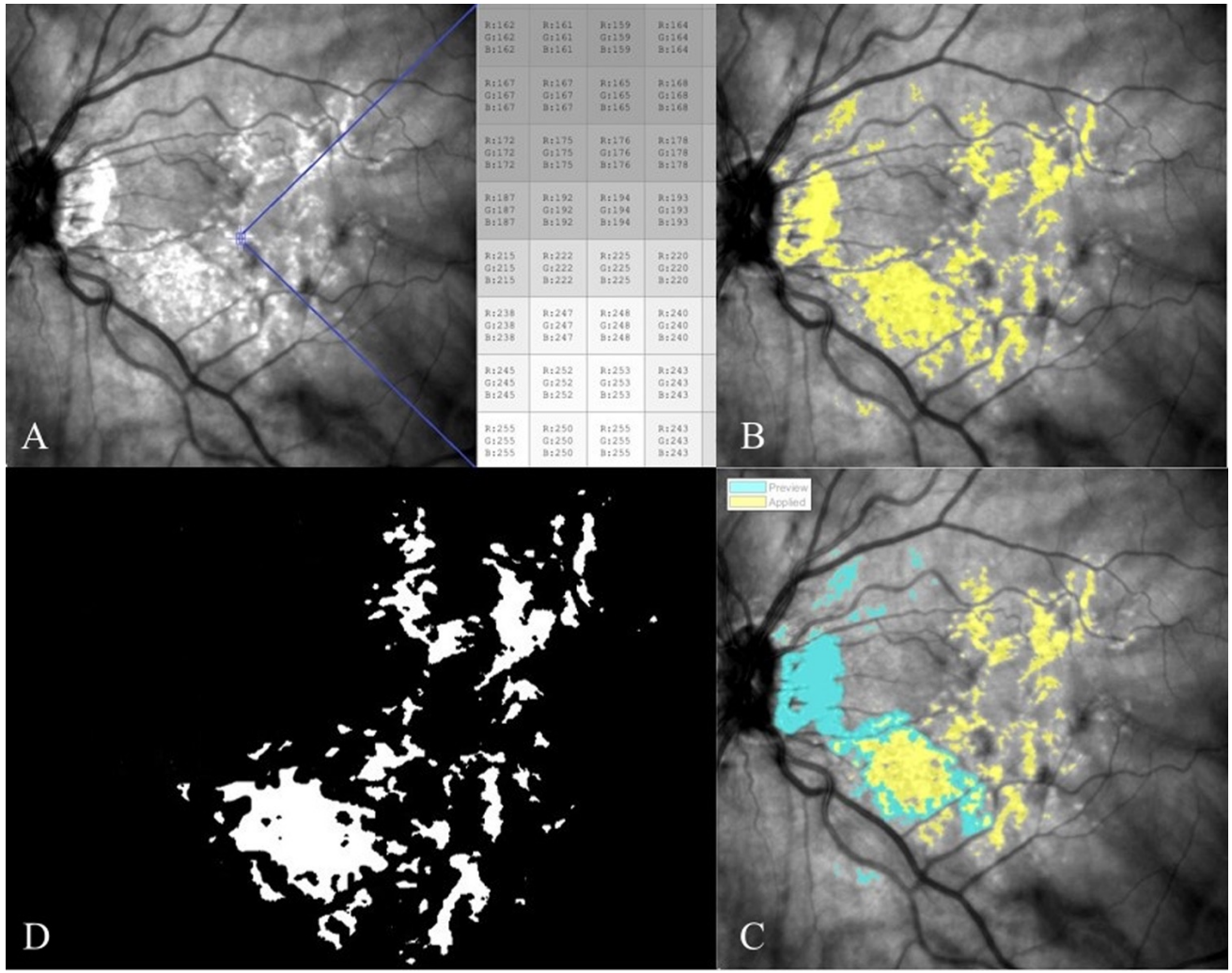

Eye **volume 37**, pages3530–3533 (2023)

Artificial intelligence for the diagnosis of retinopathy of prematurity

Eye **volume 37**, pages2518–2526 (2023)

Current uses of artificial intelligence in the analys of biofluid markers involved in corneal and ocula surface diseases

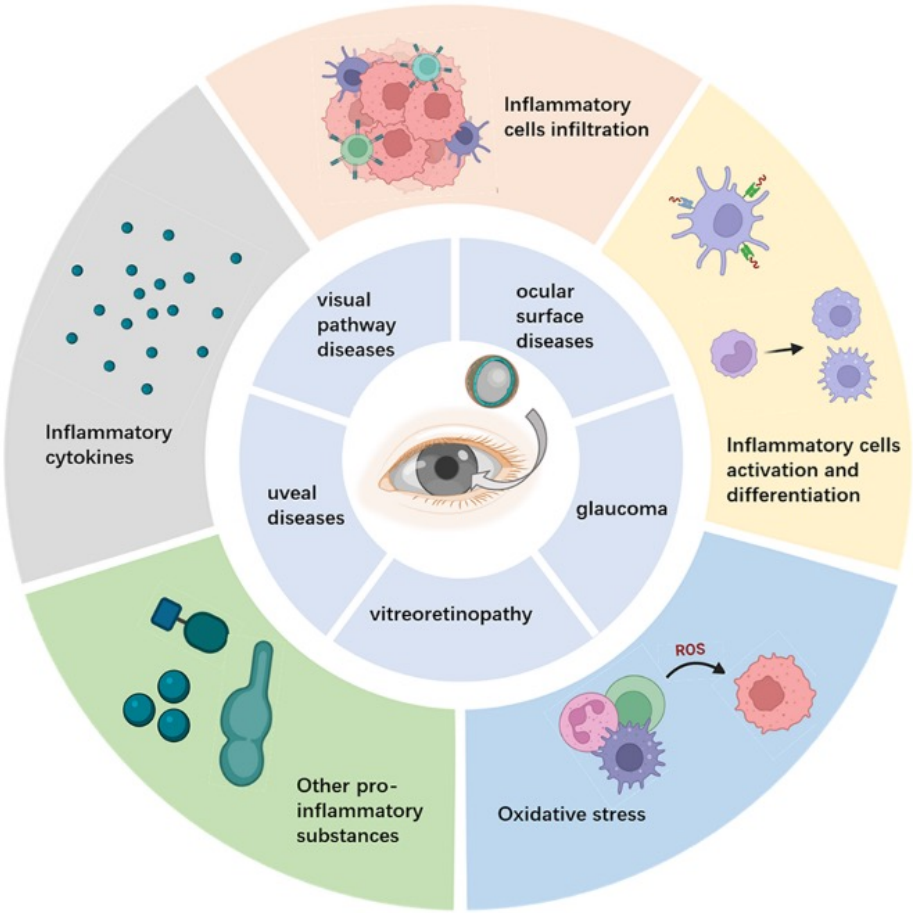

Eye **volume 37**, pages2007–2019 (2023)

Artificial intelligence to distinguish retinal vein occlusion patients using color fundus photographs

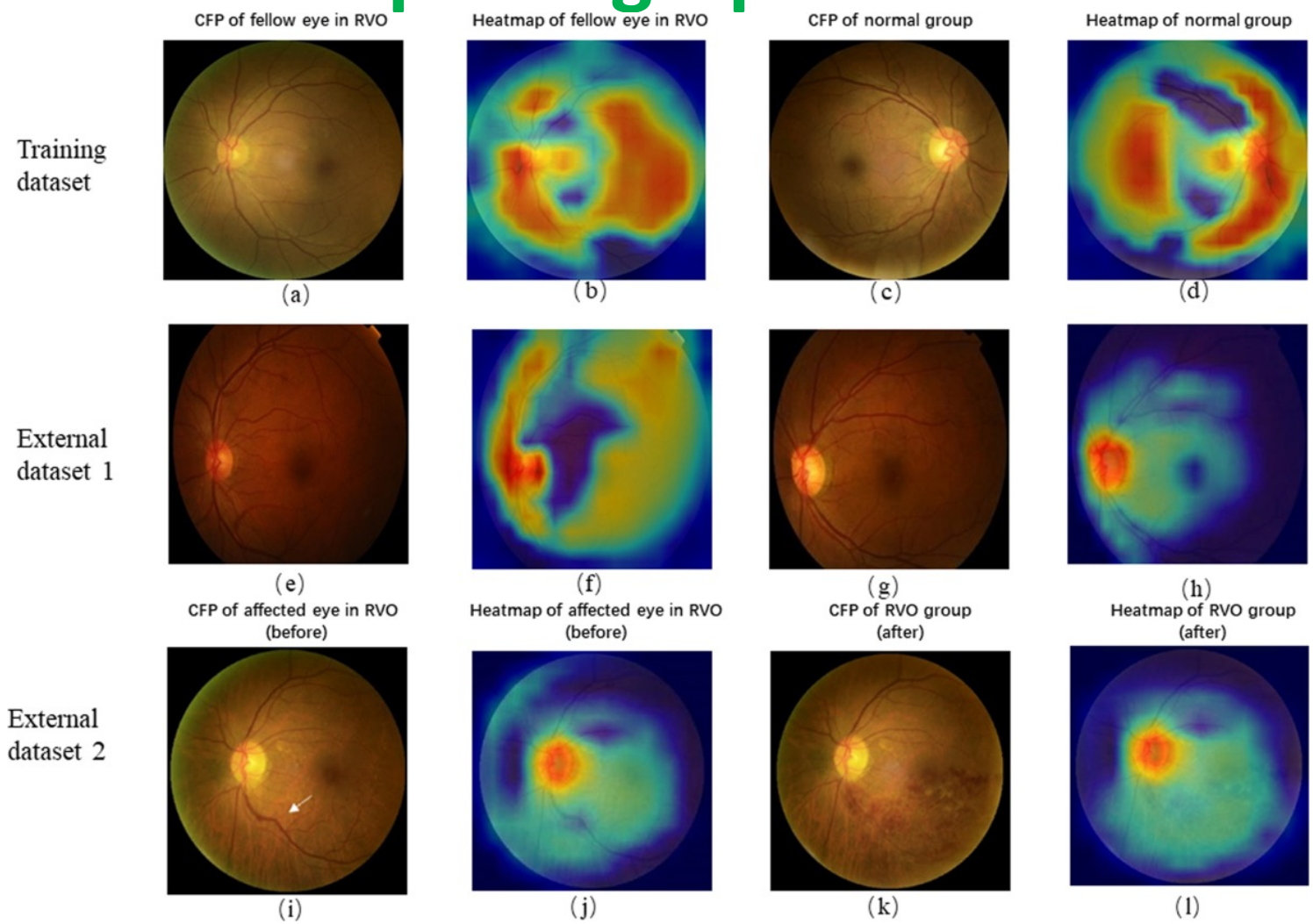

Eye **volume 37**, pages2026–2032 (2023)

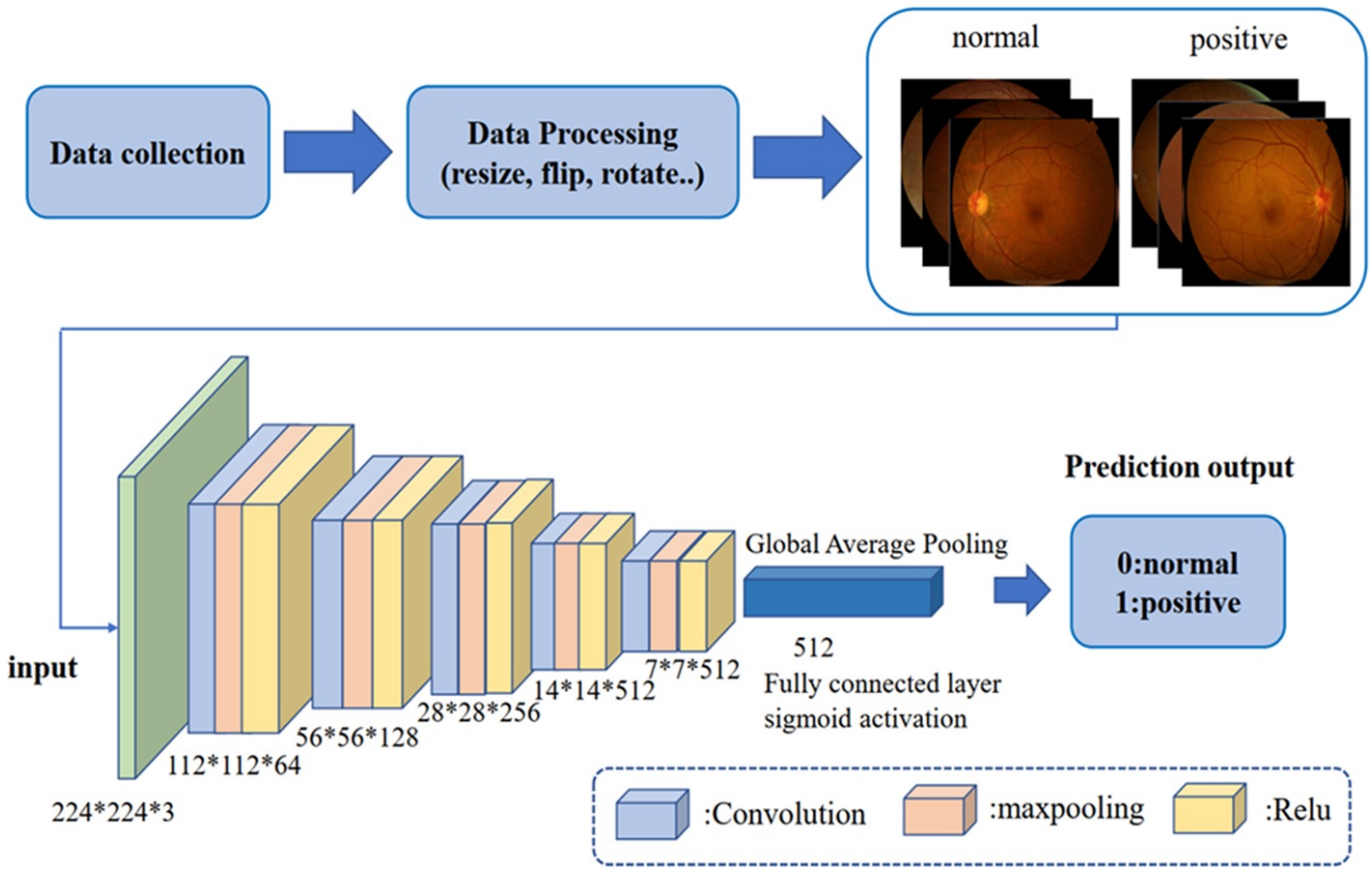
Data collection
Data Processing
(resize, flip, rotate..)
normal
positive
input
224*224*3
112*112*64
56*56*128
28*28*256
14*14*512
7*7*512
Global Average Pooling
512
Fully connected layer
sigmoid activation
Prediction output
0:normal
1:positive
:Convolution
:maxpooling
:Relu

32 Disease detection

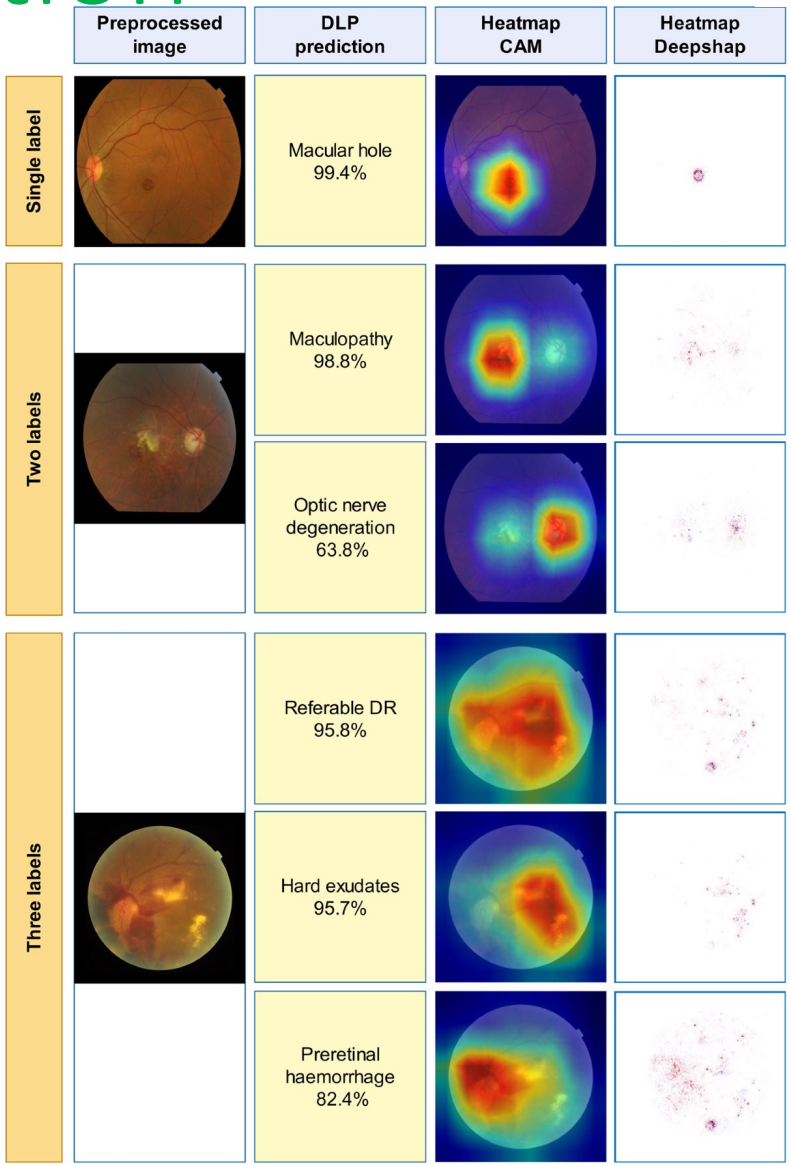

Nature Communications **volume 12**, Article number: 4828 (2021)

Personalized treatment supported by automated quantitative fluid analysis in active neovascular age-relat macular degeneration (nAMD

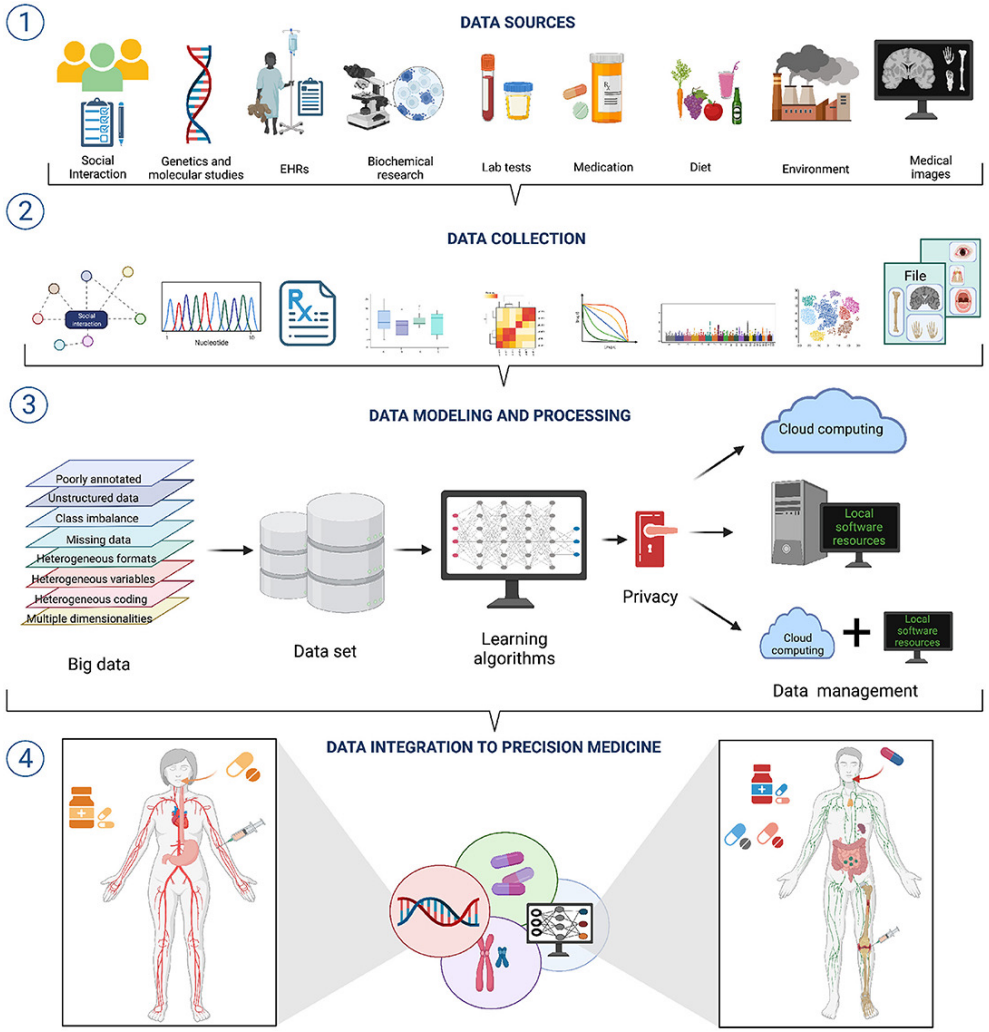

Eye **volume 37**, pages1464–1469 (2023)

Ocular Therapeutics and Molecular Delivery Strategies

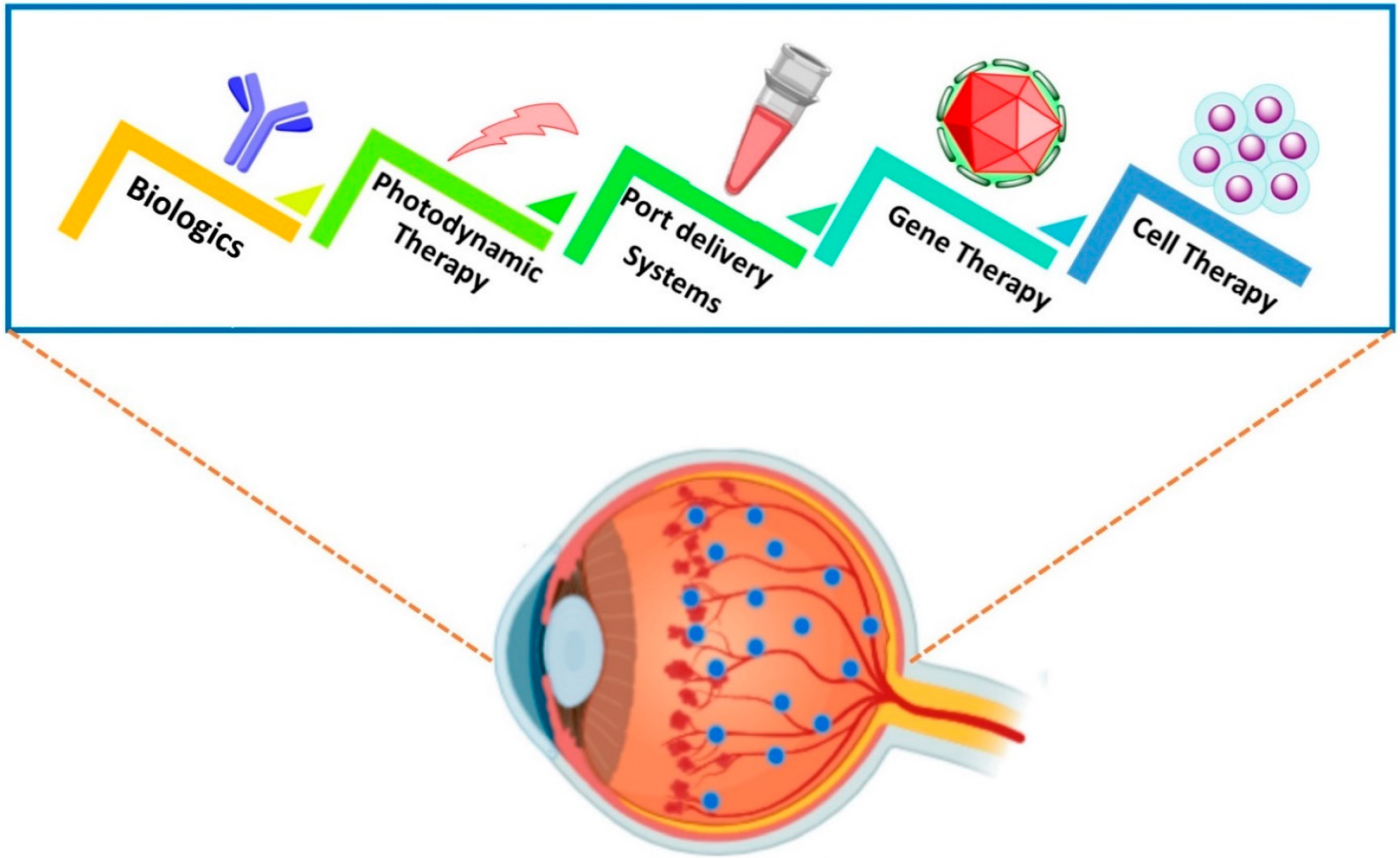

Segmentation of macular neovascularization and leakage fluorescein angiography images in neovascular age-relate macular degeneration using deep learning

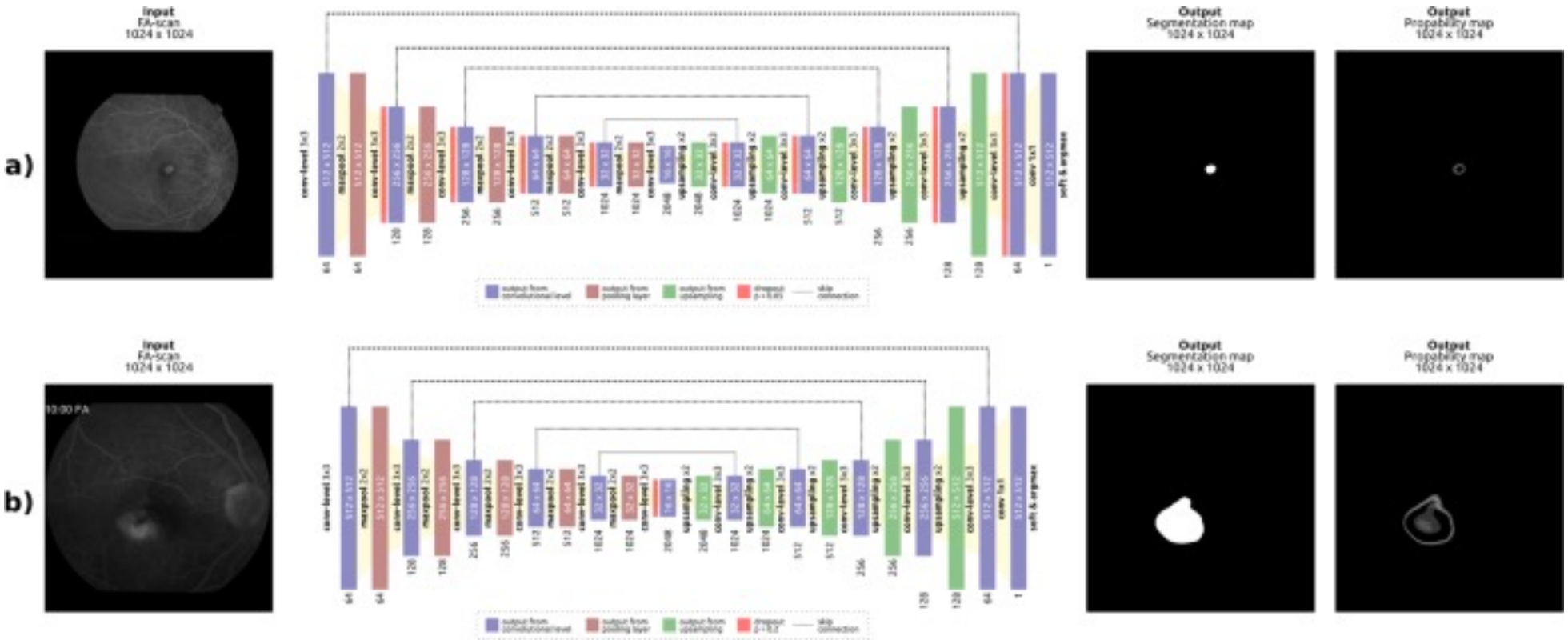

Eye **volume 37**, pages1439–1444 (2023)

Automatic detection of non-perfusion areas in diabetic macular edema from fundus fluorescein angiography for decision making using deep learning

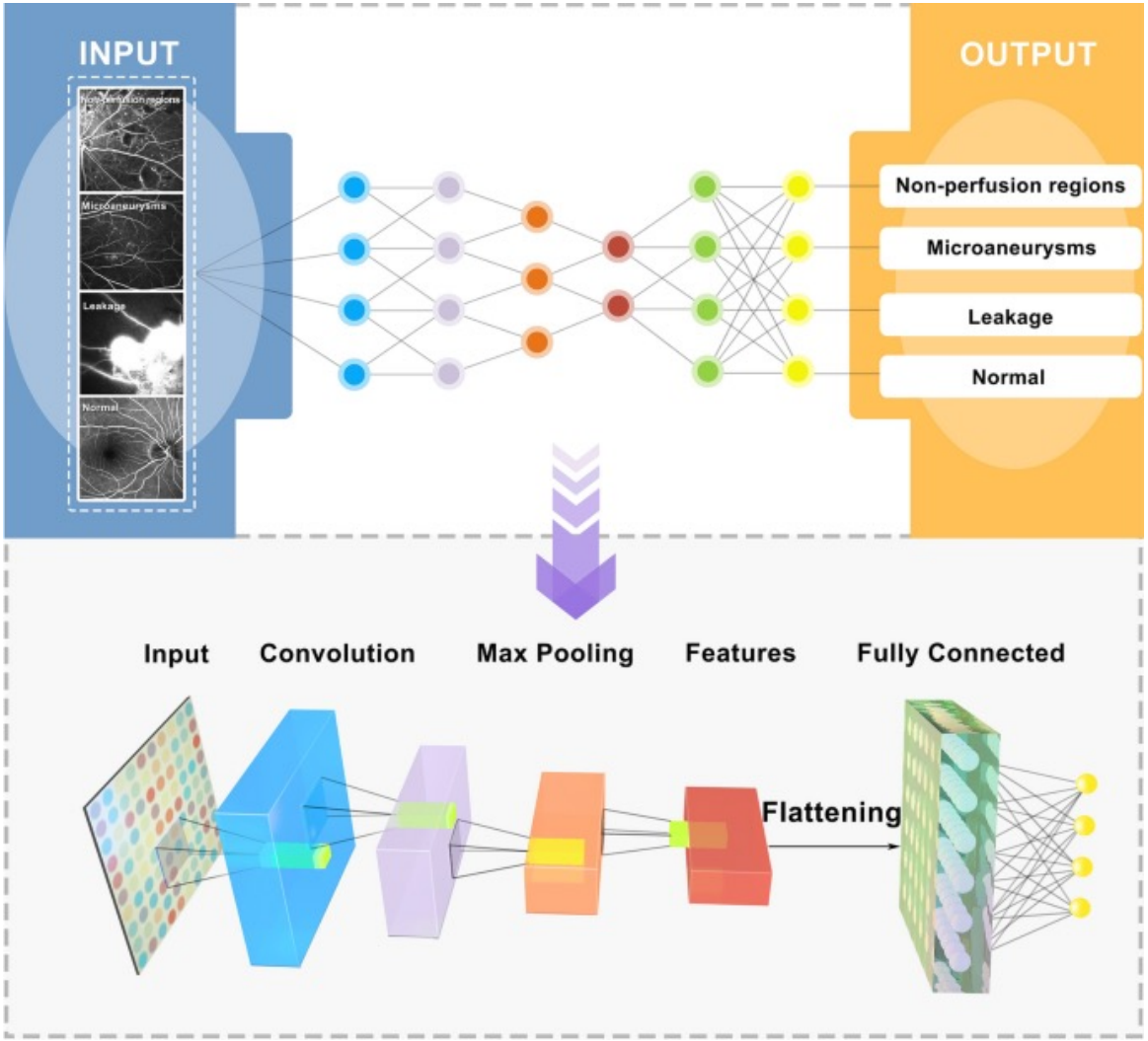

Scientific Reports **volume 10**, Article number: 15138 (2020)

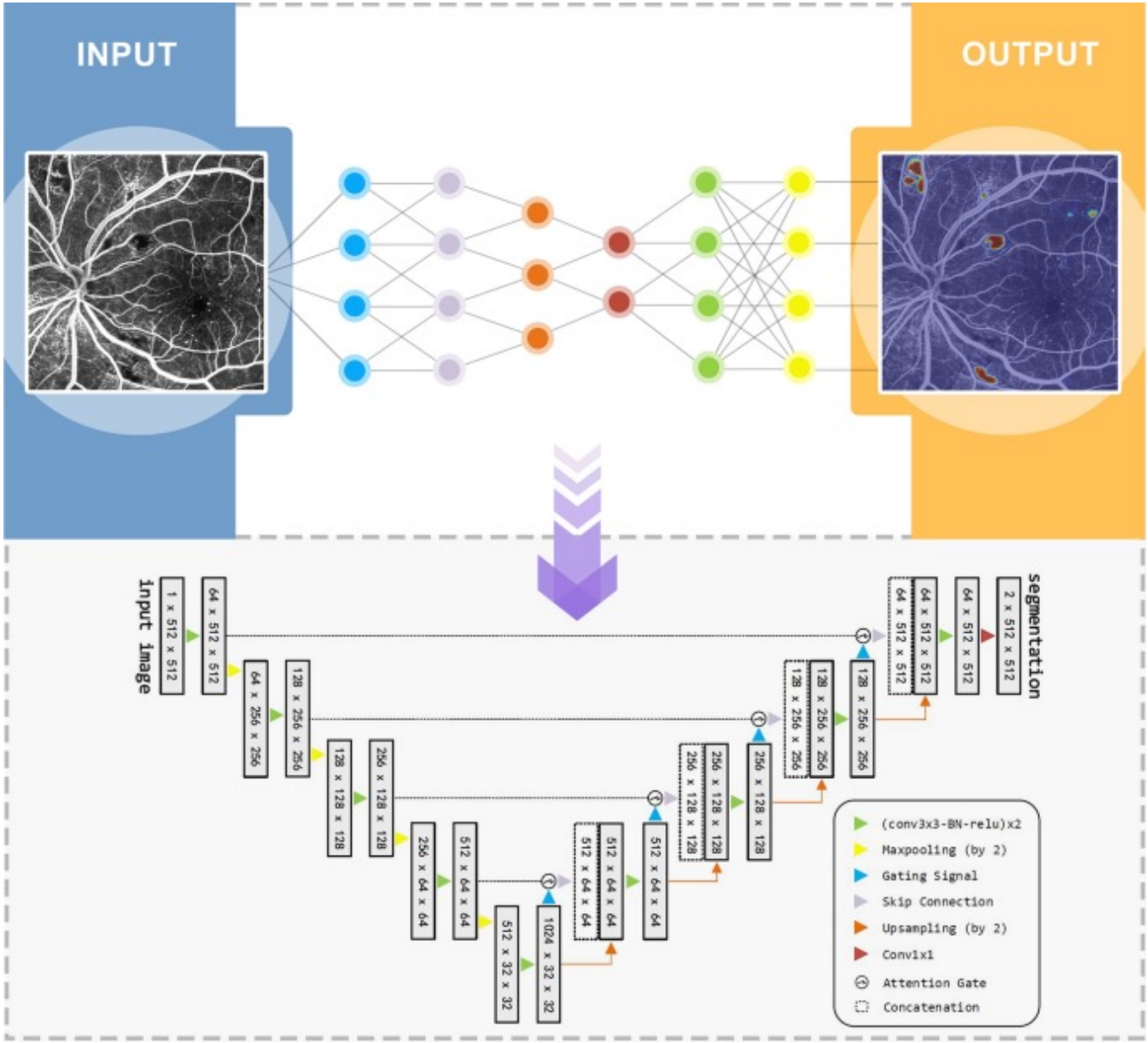
INPUT
OUTPUT
segmentation
2 x 512 x 512
64 x 512 x 512
64 x 512 x 512
64 x 512 x 512
128 x 256 x 256
128 x 256 x 256
128 x 256 x 256
128 x 256 x 256
256 x 128 x 128
256 x 128 x 128
256 x 128 x 128
256 x 128 x 128
512 x 64 x 64
512 x 64 x 64
512 x 64 x 64
512 x 64 x 64
1024 x 32 x 32
512 x 32 x 32
512 x 64 x 64
256 x 64 x 64
256 x 128 x 128
128 x 128 x 128
128 x 256 x 256
64 x 256 x 256
64 x 512 x 512
1 x 512 x 512
input image
(conv3x3-BN-relu)x2
Maxpooling (by 2)
Gating Signal
Skip Connection
Upsampling (by 2)
Conv1x1
Attention Gate
Concatenation

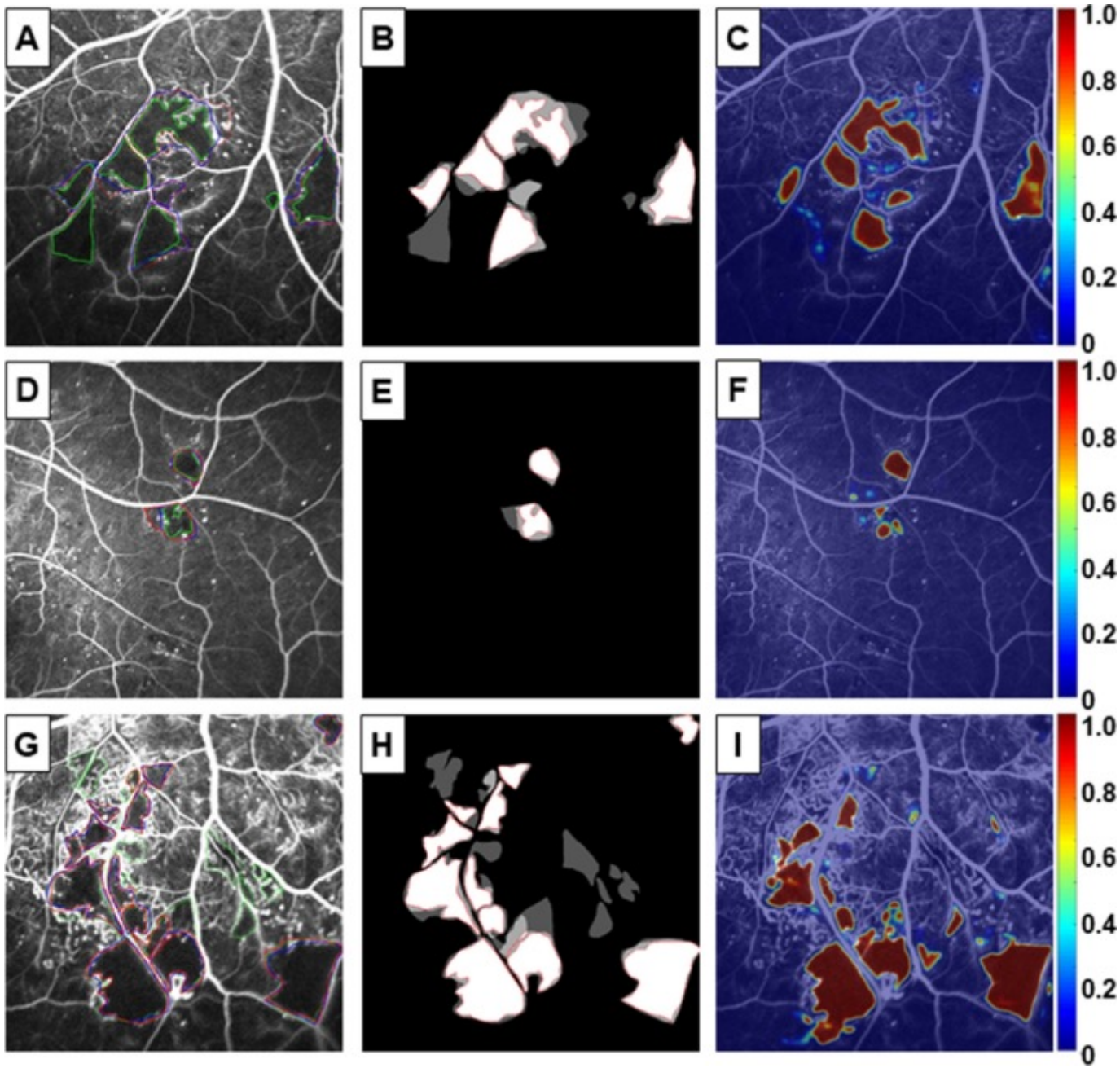
A
B
C
D
E
F
G
H
I
1.0
0.8
0.6
0.4
0.2
0

Foveal avascular zone segmentation in optical coherence tomography angiography images using deep learning approach

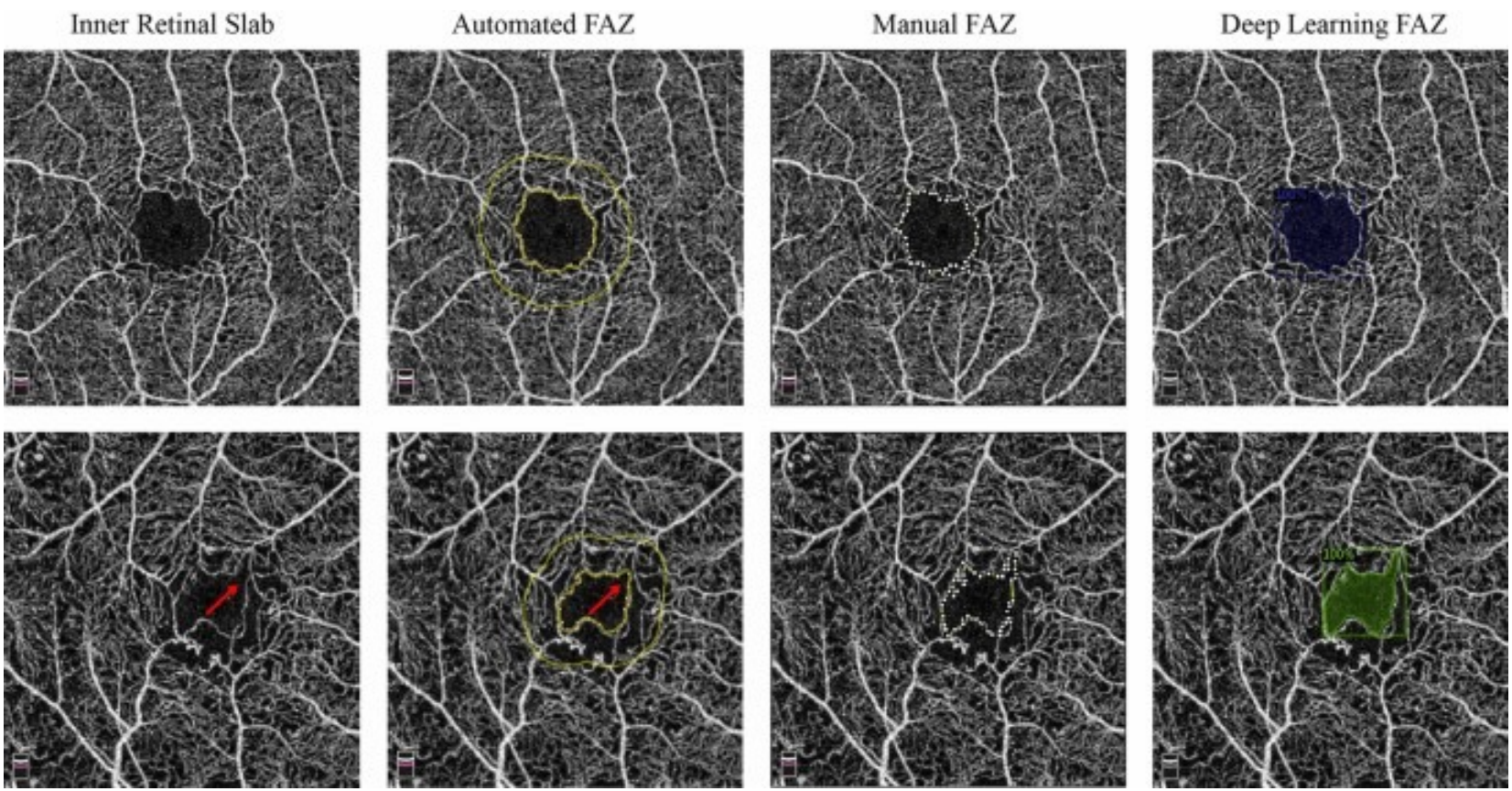

Scientific Reports **volume 11**,
Article number: 1031 (2021)

Comparison of early diabetic retinopathy staging in asymptomatic patients between autonomous AI-based screening and human-graded ultra-widefield colour fundus images

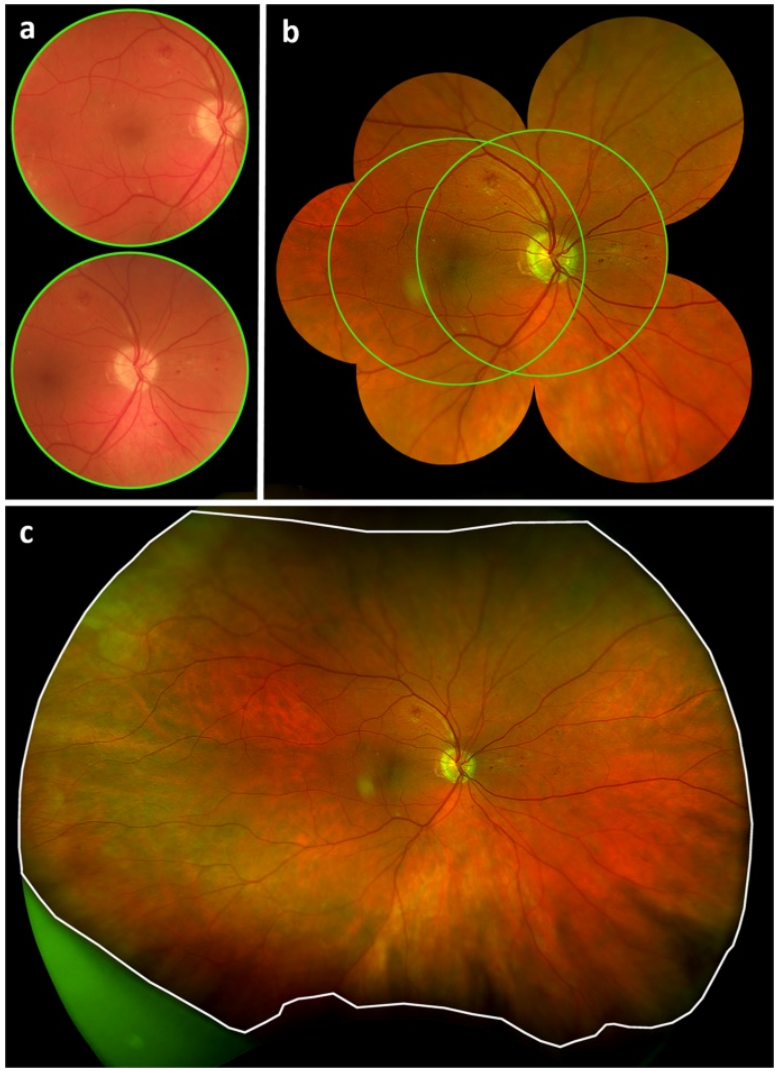

Eye **volume 36**, pages510–516 (2022)

Deep learning for predicting uncorrected refractive error using posterior segment optical coherence tomography images

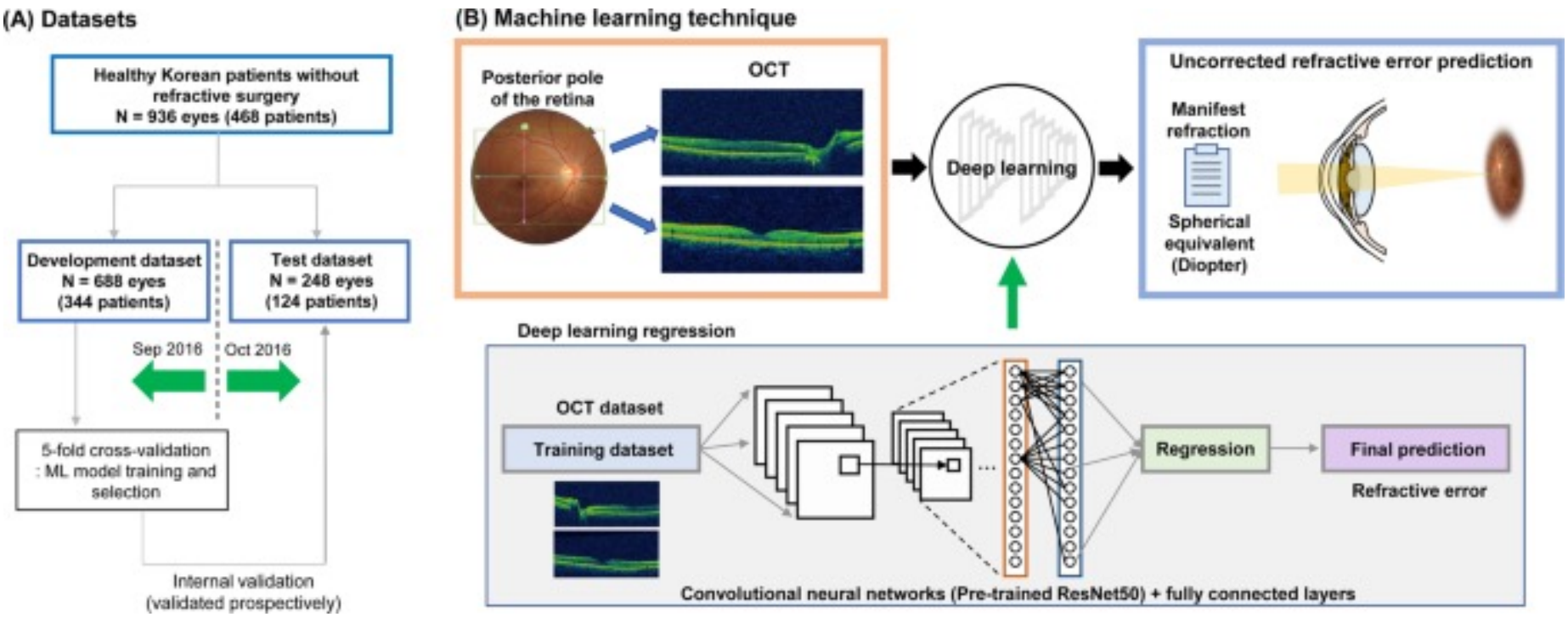

Eye **volume 36**, pages1959–1965 (2022)

Automated detection of retinal exudates and drusen in ultra-widefield fundus images based on deep learning

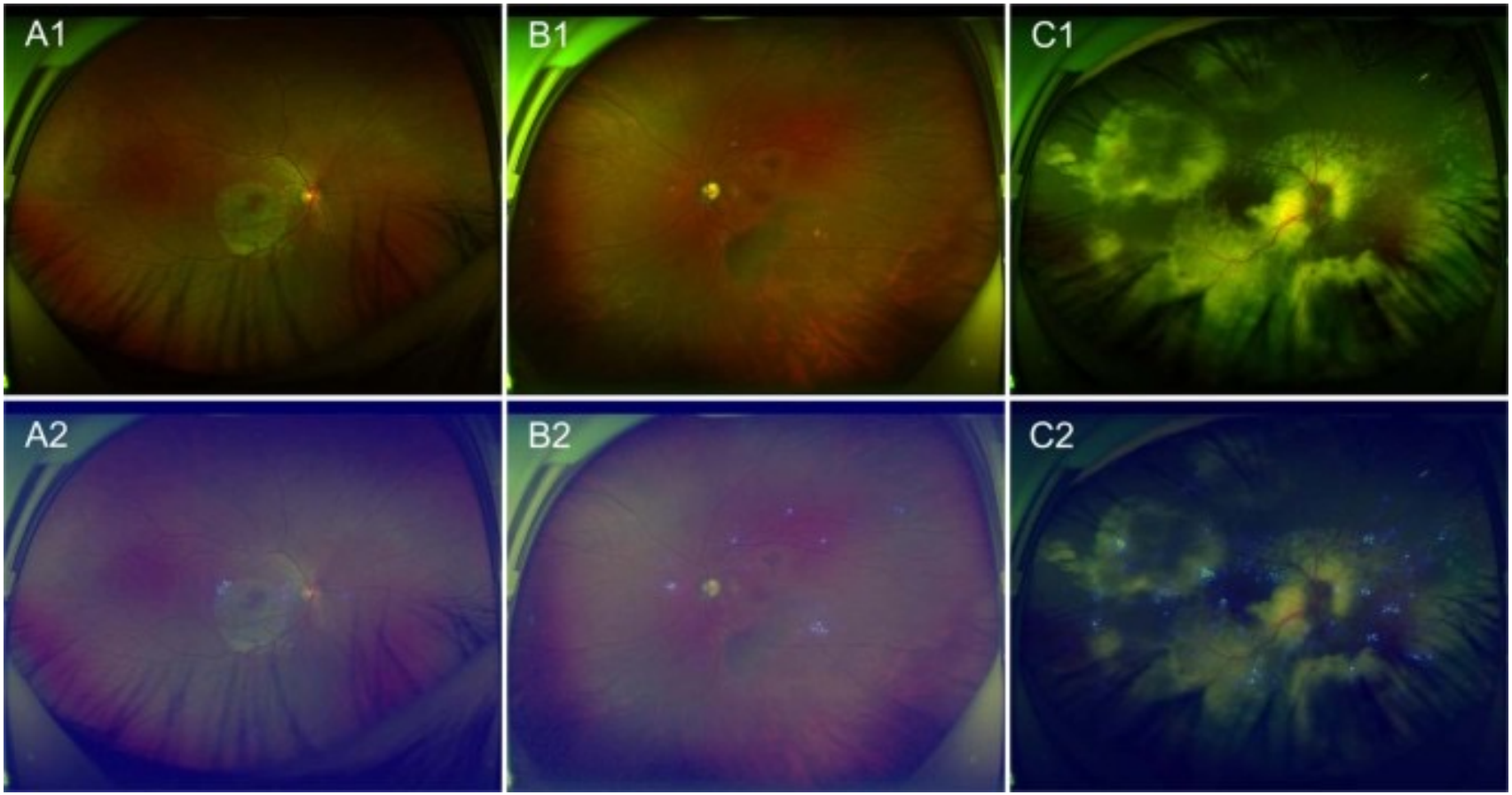

Eye **volume 36**, pages1681–1686 (2022)

Machine learning on glaucoma

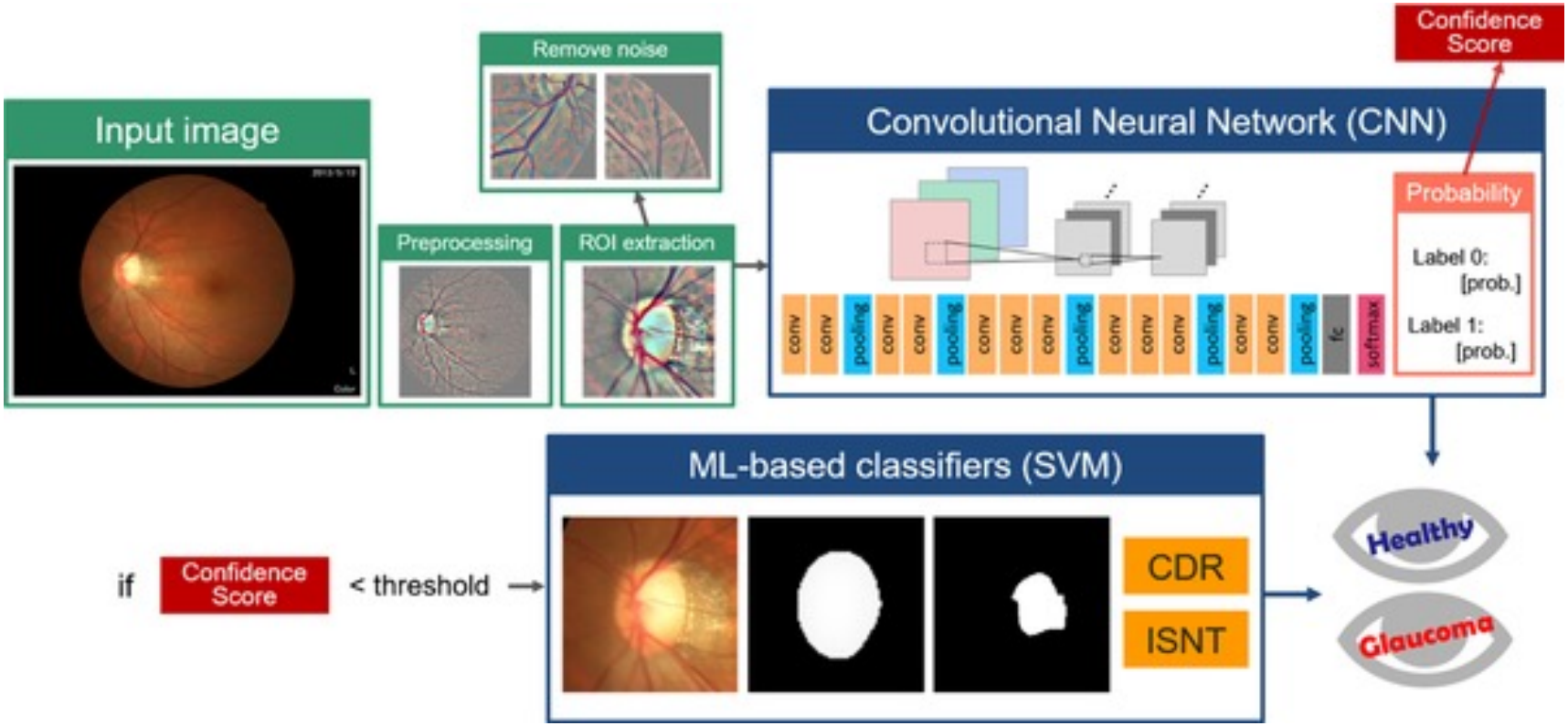

Eye **volume 35**, pages2456–2457 (2021)

Automated diabetic retinopathy detection in smartphone-based fundus photography using artificial intelligence

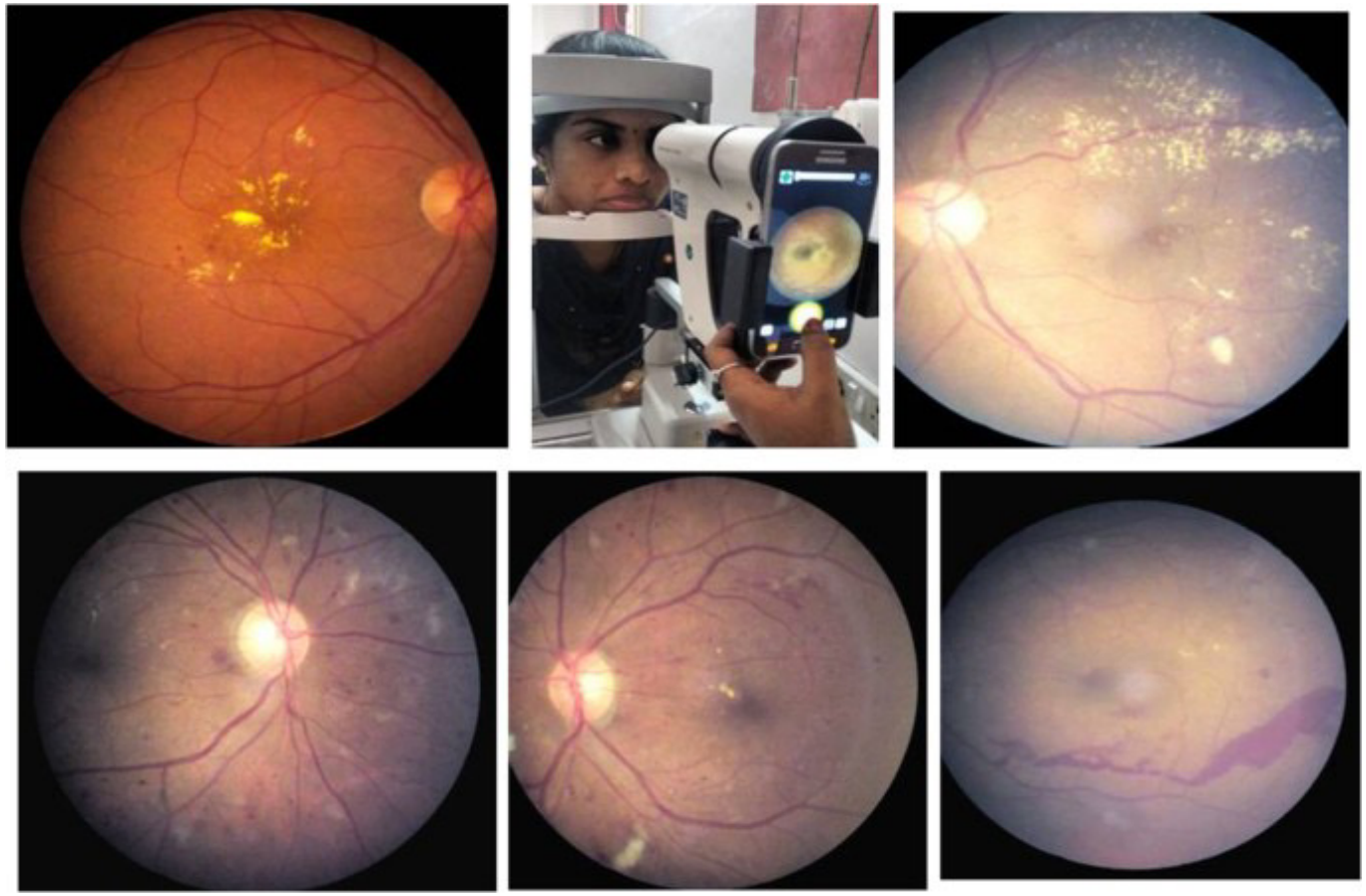

Eye **volume 32**, pages1138–1144 (2018)

Drug Delivery

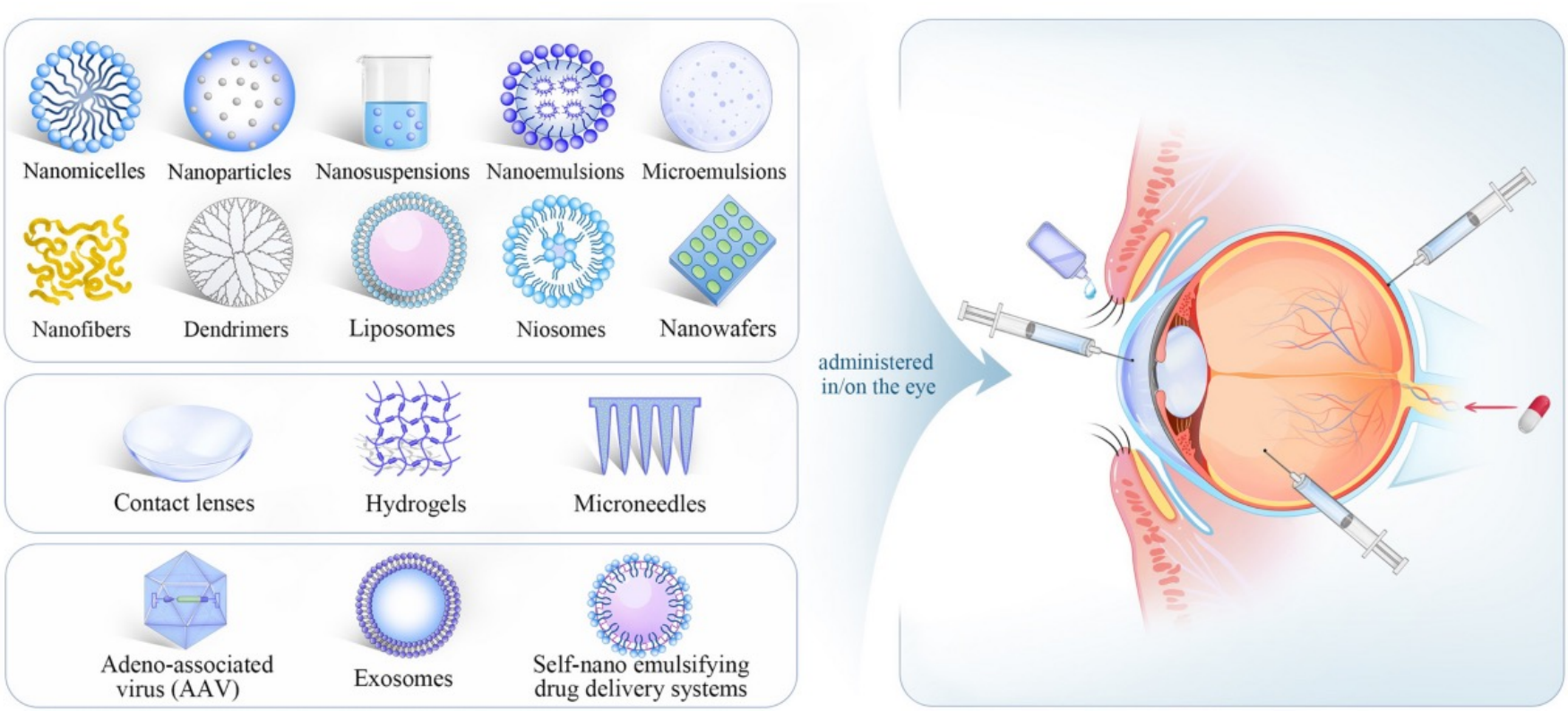

Micro, Nano and Molecular System

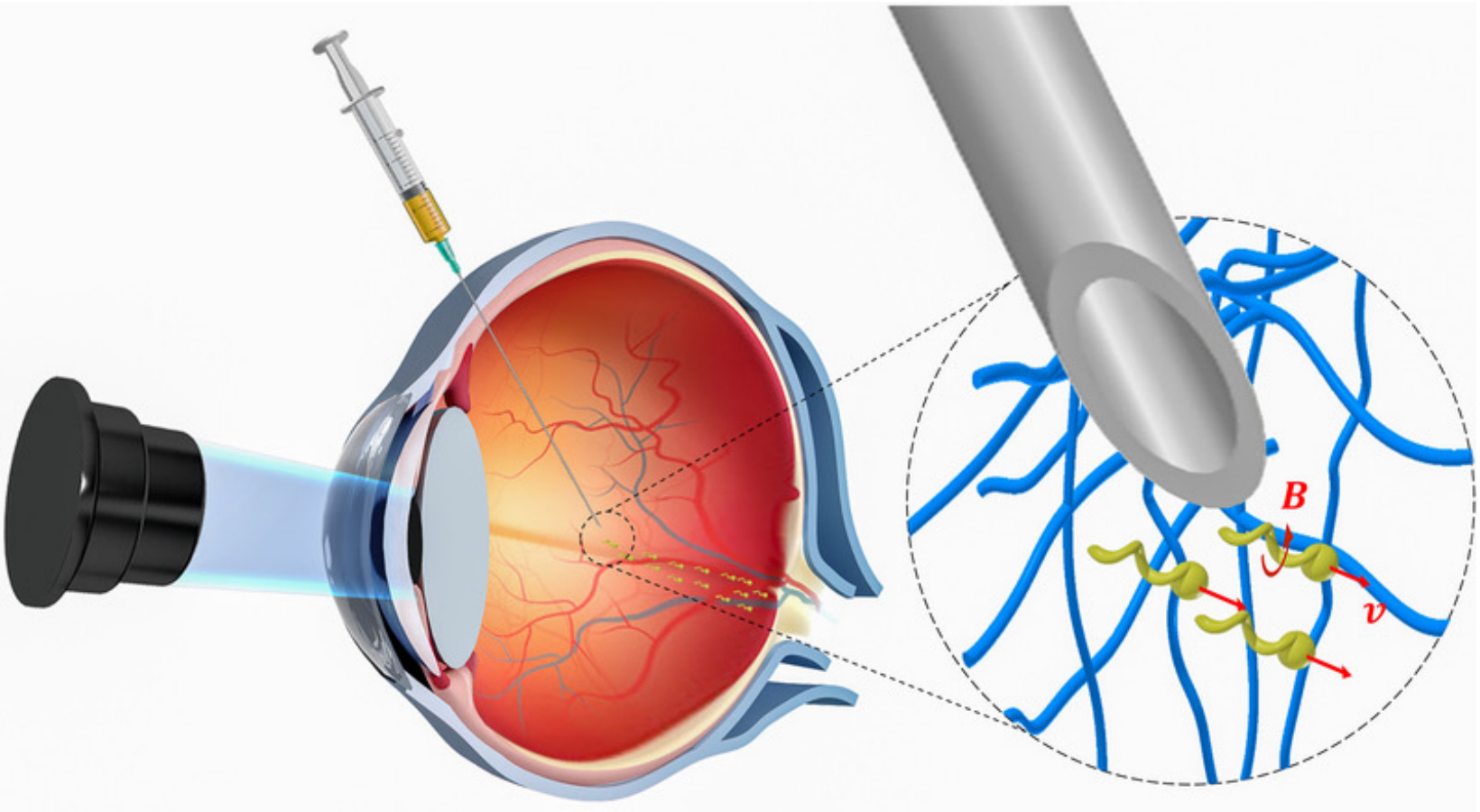

https://is.mpg.de/

Challenge 1: Size

- If the size of the micropropellers (robots) is much smaller than the mesh size of the complex network (human eyeball) it has to penetrate, then the propulsion of the nanopropellers is possible in the nanoporous medium (the eyes dense tissue, also known as, the lacrimal fluid-eye barrier and the retina–blood barrier).
- At about 500 nanometers wide, they're around 200 times smaller than the diameter of a human hair, just the right size for sliding around in the complex molecular matrix of the eyeball.

Challenge 2: move

- The second was to find a way to keep the robots from getting entangled in the eyeball's mesh of biological molecules. The robot itself is a device called a micropropellor. It uses a spiral tail to spin through the vitreous humor – a clear, jelly-like substance behind the white of eye which makes up 80 percent of the organ. But the device itself wasn't flowing through the "jelly" smoothly or as directed.
- To solve this dilemma the scientists used a perfluorocarbon liquid to coat the micropropellors and make them slippery.

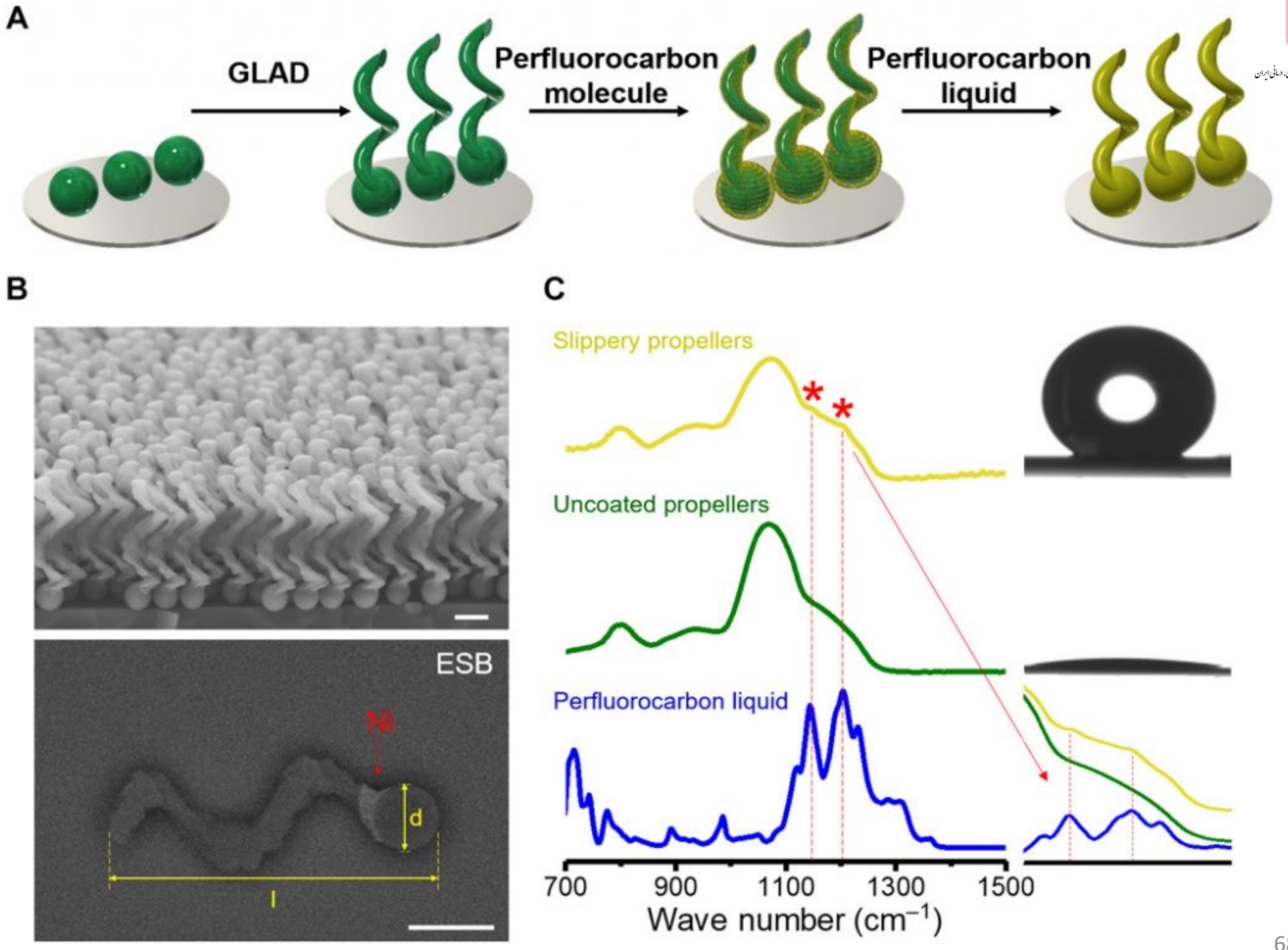
A
GLAD
Perfluorocarbon molecule
Perfluorocarbon liquid
B
ESB
Ni
d
l
C
Slippery propellers
Uncoated propellers
Perfluorocarbon liquid
700
900
1100
1300
1500
Wave number (cm^{-1})

Challenge 3: Target

- The third challenge was guided maneuverability, in other words, how to navigate the robots to the desired location through the eyeball.
- magnets. The tails of the robots were seeded with tiny metal particles (made of nickel) that respond to an external magnetic field.
- The external magnetic field is the control board where the doctor can guide the robot(s) to the desired location within the eye. \

Nanomedicine



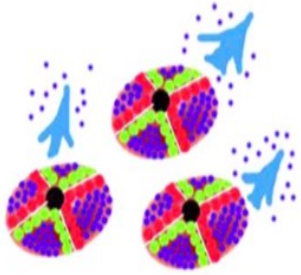

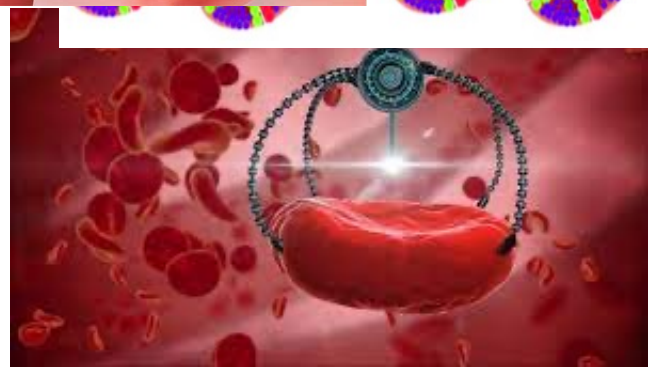

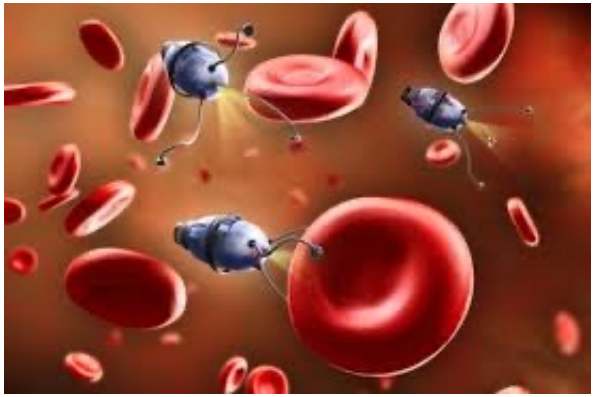

[1] N. Rady Raz, M. R. Akbarzadeh T., "Target Convergence Analysis of Cancer Inspired Swarms for Early Disease Diagnosis and Targeted Collective Therapy,"*IEEE Transactions on Neural Networks and Learning Systems*, 2022.

[2] N. Rady Raz, M. R. Akbarzadeh T., "Swarm-Fuzzy Rule-Based Targeted Nano Delivery Using Bioinspired Nanomachines,"*IEEE Transactions on NanoBioscience*,Vol.18, No.3, pp. 404 - 414, July 2019.

[3] N. Rady Raz, M. R. Akbarzadeh T., M. Tafaghodi, "Bio-Inspired Nanonetworks for Targeted Cancer Drug Delivery,"*IEEE Transactions on NanoBioscience*,Vol.14, No.8, pp. 894-906, Dec. 2015.

Microrobotics meets nanomedicine for improved eye surgery

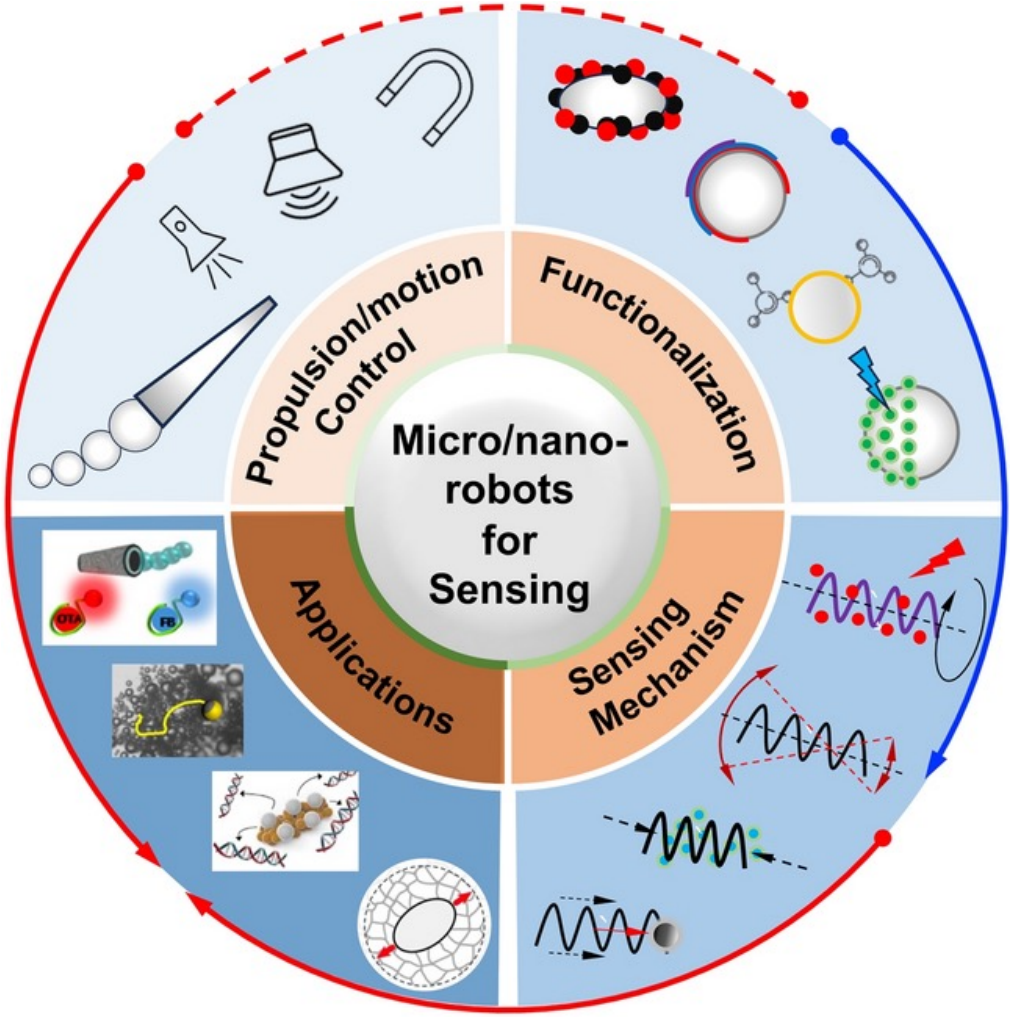

personalized dry eye relief

3D EYE SURGERY

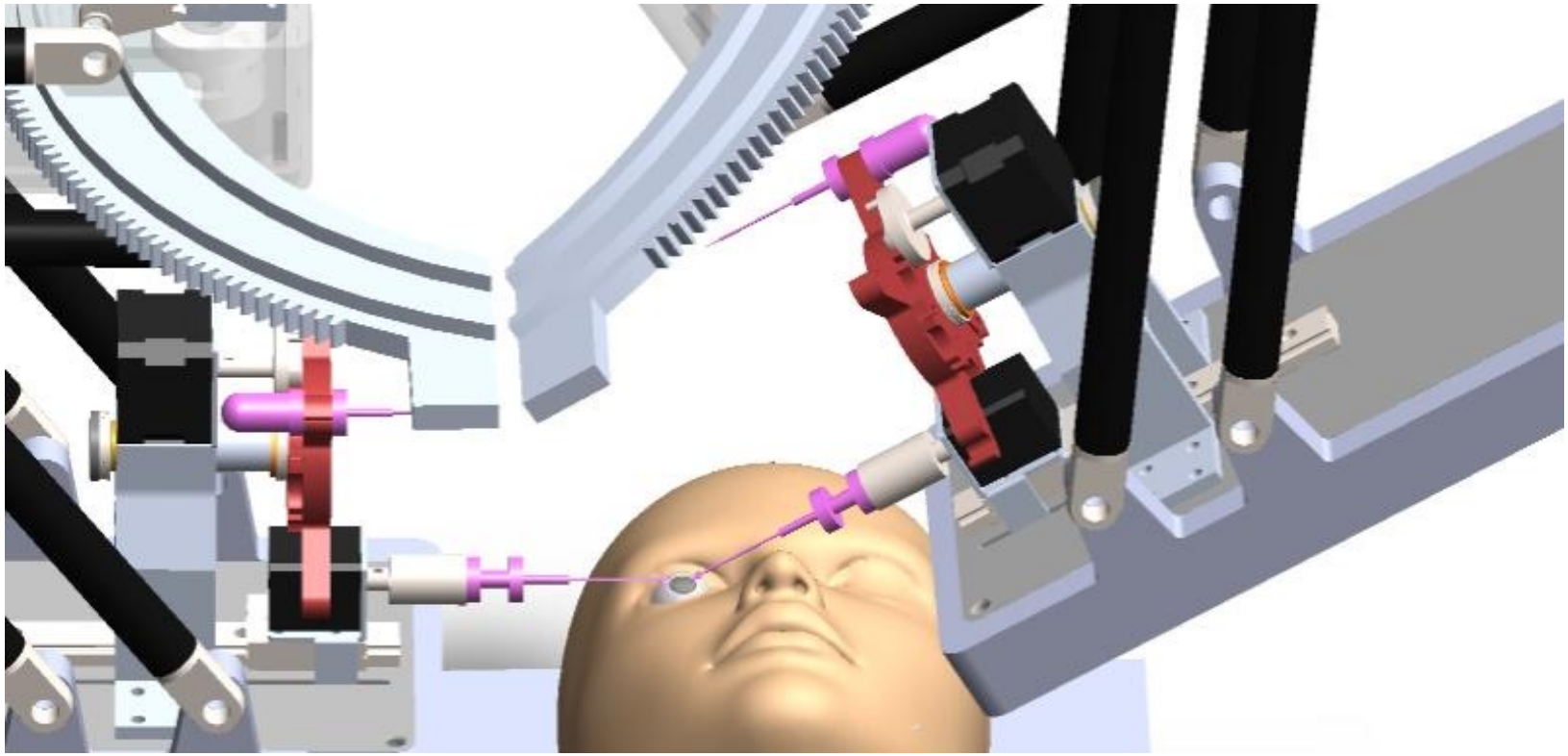

Figure 1. The Procyon robotic-assisted platform uses a robotic arm operated directly by the surgeon (A), with a conical port adapter to allow insertion of surgical tools into the eye (B). (Courtesy Procyon)

Telesurgery

Digital Operating Room for Retinal Surgery

Section 2:How to perform AI in ophthalmology

Introduction

- The introduction of the manuscript should describe unmet clinical needs, unique features of the AI system, and how the AI system described aims to fulfill said clinical needs.

Methodology

- In the methodology, the datasets and the AI method, such as an artificial neural network, are the two main components required for AI-based medical image analysis.
- Three main aspects need to be evaluated here: the input to the AI, the way the AI processes the input, and the AI outputs.

(1) Input to the AI

- Input data could be clinical data, medical images, genomics.
- Fundus photography and optical coherence tomography (OCT) are the most commonly studied ocular images.
- fundus photography, the laterality, fields of view (30, 45, 50° or a wide field), and views of the field (optic disc or macula-centered) should be stated.
- For OCT-based AI studies, the site of the eyes, direction of the scan (vertical or horizontal), and the number of included scans (subfoveal only, central 11 cuts, or total slabs) should be stated.

Is there a minimum size required for the training dataset?

- Similar to a statistical analysis in a clinical trial, AI performance increases based on the volume of training data, with some variability based on the AI's "task", quality of the images, and ground truth.
- Thus, there is no one-answer-fits-all answer for the quantity of data needed. Several studies have reported ways to determine sample size needed to develop AI models, such as estimation using a learning curve.
- Methods to determine the sample size needed for the evaluation of AI include well-studied statistical power calculations for the evaluation metric (such as sensitivity or specificity).

(2) AI processing

- The most common type of DL method used for medical images is the convolutional neural network (CNN). Several types of layers that can be found in a CNN include convolutional layers, pooling layers, fully connected layers, and normalization layers.
- Each artificial neuron contains a weight that is multiplied with its input and frequently “thresholded” to determine whether it should “fire”. These weights are automatically learnt during the process of training by exposing the network to many examples. Therefore, training a DL model does not require the manual crafting of predictive features that is needed for ML.
- To reduce the need for large labeled datasets, transfer learning may be used to help the AI learn from other image interpretation tasks instead of starting from scratch.

hyperparameters

- Although AI systems learn from examples during the training process, several settings need to be prespecified before training.
- These settings are called “hyperparameters” , and include the learning rate, batch size, momentum, and weight decay.
- Many of these hyperparameters define how the AI system learns from the data. Because these hyperparameters require extensive trial and error, a separate “validation/tuning” dataset is needed to fine tune these hyperparameters.

- To accomplish the above, the collected datasets are generally split into train, validation, and test sets. Because of terminology differences between fields, the “validation set” is sometimes called the tuning set;
- and the test set is sometimes called the “clinical validation set” or “holdout set”. Some common options for splitting datasets are 6/2/2, 7/2/1, or 8/1/1, though these ratios are empirical.
- Cross-validation can also be used to minimize the sampling bias from splitting of datasets, though its use in development (multiple training/validation splits) versus evaluation (multiple testing splits) has different goals and beyond the scope of this article.

complexity of the algorithm

- What may come as a surprise to some readers new to DL is the complexity of the algorithm that processes the input to produce the output.
- Though the exact weights and multiplications used are known precisely, there are typically millions or billions of such mathematical operations, which makes understanding it difficult.
- As such, some have labeled such methods a “black box”. Clinicians may understandably be reluctant to accept research outcomes and clinical decisions made through algorithms that are not completely understood.

Output of the AI

- AI performance is evaluated by comparison with a reference standard, which is often a widely accepted gold standard or ground truth.

Result Section

- The result section quantifies the performance of the AI system by reporting the measures of discrimination, such as the area under the curve (AUC), sensitivity (also called true positive rate or recall), specificity (equivalent to 1—false positive rate), positive predictive value (PPV), and negative predictive value (NPV):

2-AUC

- (1)AUC: AI performance can be described by receiver operating characteristic (ROC) curves and precision–recall curves.
- ROC curves summarize the trade-off between the true positive rate (*y*-axis) and the false positive rate (*x*-axis) using different thresholds.
- Precision–recall curves summarize the trade-off between the PPV (*y*-axis) and the true positive rate (*x*-axis).
- The AUC measures the entire two-dimensional area underneath the ROC curve; hence, providing an aggregate measure of performance across all possible classification thresholds. An algorithm with a 100% accuracy compared with the “reference standard” has an AUC value of 1.0.

3-Sensitivity and specificity

- sensitivity and specificity should be demonstrated on the independent datasets performed at the same operating threshold. Sensitivity and specificity are generally not influenced by the prevalence of the disease if there is no spectrum bias.

$$\text{Sensitivity} = \frac{\text{True Positives}}{\text{True Positives} + \text{False Negatives}}$$

$$\text{Specificity} = \frac{\text{True Negatives}}{\text{True Negatives} + \text{False Positives}}$$

(3)Predictive values

- PPV is the proportion of cases that truly have the target condition among cases with positive test results. NPV is the proportion of cases that truly do not have the target condition among cases with negative test results. Unlike sensitivity and specificity, predictive values are affected by the prevalence of the disease. PPV increases while NPV decreases as the prevalence increases.

(4)Interrater comparisons

- such as Cohen's *k* value, are used to evaluate whether there is an agreement between interpretations. In an AI study, it is usually used to describe the interrater agreement between an algorithm and reference standard or human graders. It does not reflect the true accuracy of the test.

values ≤ 0 as indicating no agreement and 0.01–0.20 as none to slight, 0.21–0.40 as fair, 0.41– 0.60 as moderate, 0.61–0.80 as substantial, and 0.81–1.00 as almost perfect agreement

(5)The diagnostic accuracy or the effectiveness of a test

- is the ability to discriminate between the target condition and health correctly in binary classification.
- It is calculated by the proportion of correct predictions (including both positive and negative predictions) among all evaluated cases. It is affected by the prevalence of the disease. The diagnostic accuracy generally increases as the prevalence grows. Therefore, diagnostic accuracy or the effectiveness of a test should be considered in a holistic manner by looking at multiple evaluation metrics.

- In the discussion, validation in a clinical setting should be clearly stated as the ultimate goal of an ophthalmic AI system is to enhance patient care in a real-world clinical environment.
- The generalizability of the developed AI system to external validation sets not used for AI development should be evaluated.

Comparisons across reported AI systems ..

- Comparisons across reported AI systems are challenging as each system's performance has been tested using different methodologies on different populations, with different input datasets.
- In a fair comparison, AI systems need to be subjected to the same independent test set that is representative of the target population, using the same performance metrics.
- As this is not always possible, the strengths and weaknesses of each paper should be reported.

- Current AI systems are capable of diagnosing and staging ocular diseases from images, such as color fundus photographs, OCT, or the visual field.
- Most algorithms have been tested on limited datasets with relatively homogenous patient populations and a selected set of imaging devices with inclusion criteria that exclude complex pathologies or poor-quality input data for study purposes.
- Real-world ocular images inevitably include indecipherable scans from diseases not yet medically identified or an overlap of multiple diseases.
- Future studies should focus on validating algorithms on real-world ocular images from multiple patient populations and using various types and versions of imaging machines.

Challenges and Ethical Considerations

data privacy,

potential biases in datasets

interpretability of algorithms,

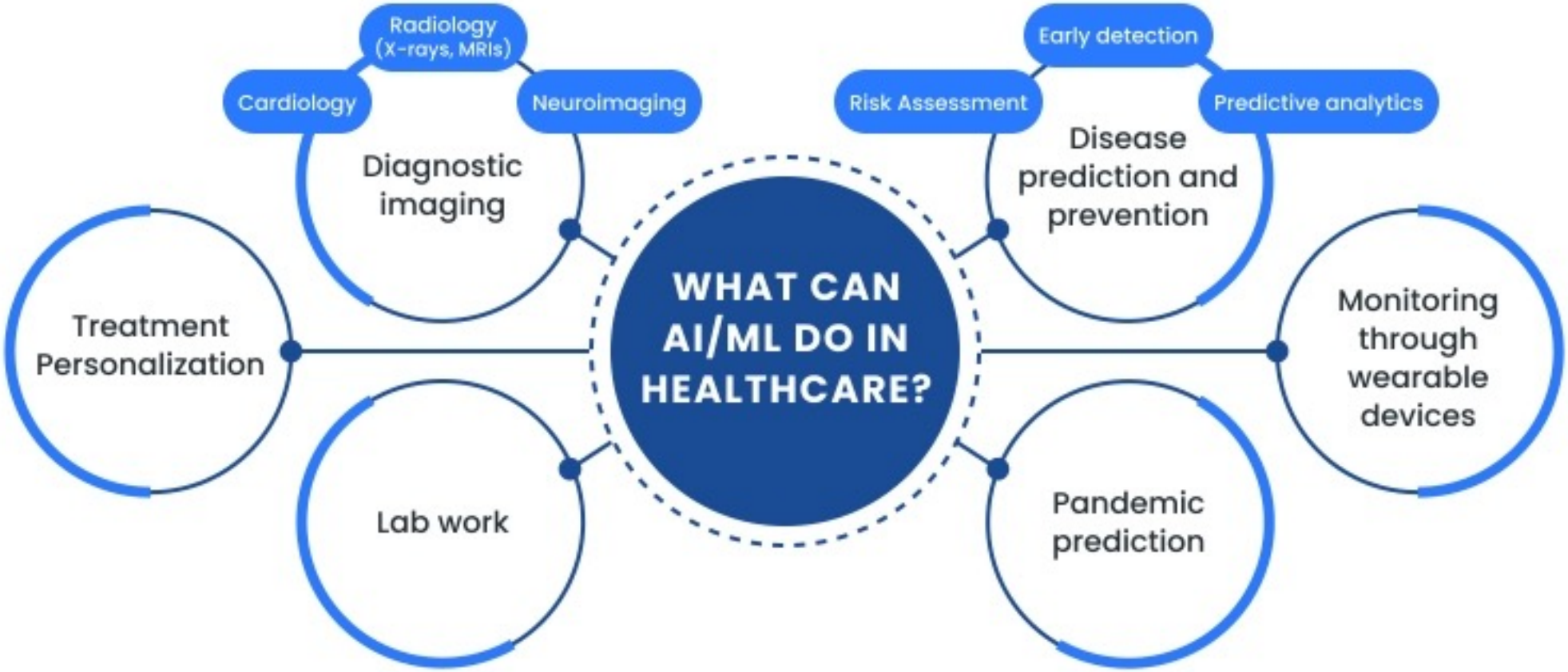

Note that!!

- AI may not replace human doctors.
- Since doctors are trained to not only diagnose and treat diseases but also to provide emotional support to patients.
- AI cannot replace the empathy and compassion that doctors bring to their work.

8-AI Medical Application

Prevention	Screening
Early Detection	Diagnosis
Recurrence Prediction	Critical Decision Making
Treatment Selection and Analysis	Mortality and Morbidity Prediction
Triage	…

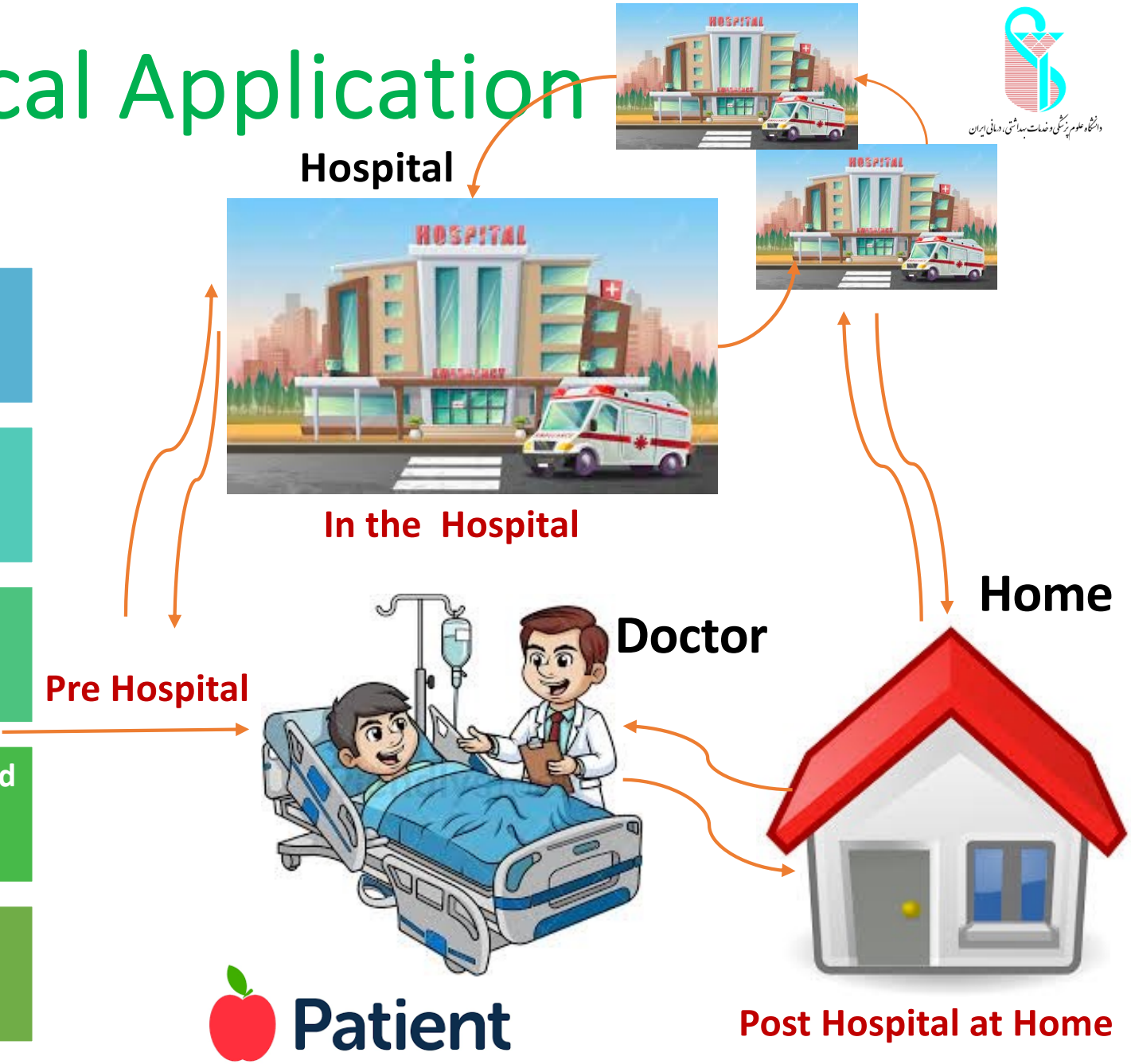

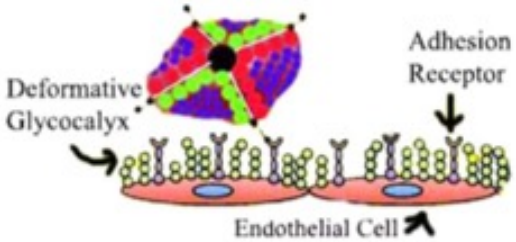

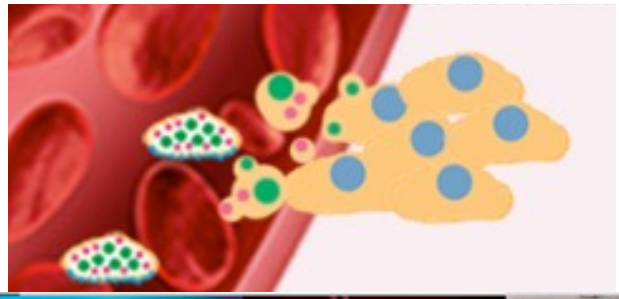

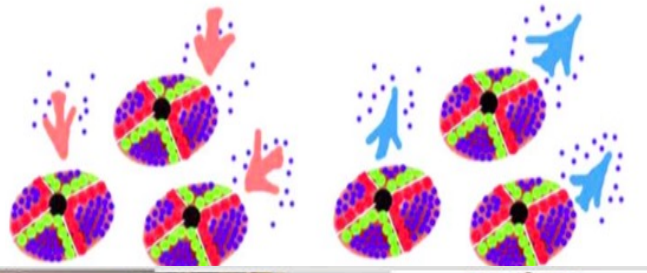

Nasibeh Rady Raz, Ph.D.

Department of Artificial Intelligence in Medicine, Faculty of Advanced Technologies in Medicine, Iran University of Medical Sciences, Tehran, Iran

MA, Ph.D., and Postdoc in Artificial Intelligence and Robotics

Website: http://radyraz.student.um.ac.ir/

Email: radyraz.n@iums.ac.ir , radyraz@mail.um.ac.ir, radyraz@yahoo.com

Research Interest:

Artificial Intelligence, Artificial Intelligence in Medicine, Complex Systems, Biomimicry, Cognitive Science, Swarm Intelligence, Nanomedicine, Targeted Drug Delivery, Early Detection of Disease, Swarm Nano Robotics, Cancer Research, Fuzzy Logic and Control, Soft Computing, Neural Networks, Machine Learning, Multi-agent Systems, Distributed Decision Making, Biomarkers, Biophysics, Nature Inspired Algorithms, Computational Cellular/Molecular Biology, Protein Folding

Artificial Intelligence for Good (AI for Good)